THE NORTHERN HOSPITAL

VALVULAR HEART DISEASE - PULMONARY STENOSIS

"Echo", oil on canvas Talbot Hughes, 1900

The signs of contraction of the pulmonic valves are the same as those of the aortic, (p. 365) with this difference; that, from the vessel being nearer the surface the murmur with the first sound seems closer to the ear, and is on a higher key, ranging from a sound of a whisper r towards that of s. I have, however, known it fall below r when the circulation was feeble and slow, and the obstruction slight. It may been known that the murmur is not seated in the aorta, by its being inaudible, or comparatively feeble, two inches up that vessel; whereas, at a corresponding height up the pulmonary artery, it is distinct: also, by its being louder down the tract of the right ventricle than down of the left (Bowden). It may be known that the murmur does not proceed from regurgitation through the auricular valves, by its being distinct along the course of the pulmonary artery, where auricular murmurs are either wholly inaudible, or very feeble and remote.

When a murmur in the pulmonary artery is considerably louder between the second and third left ribs, close to the sternum, than opposite to the valves, and is there attended with impulse and purring tremor, dilatation of the pulmonary artery may be suspected (see Dilatation of Pulmonary artery). In one instance I have known a murmur to be produced by complete ossification of the pulmonary artery penetrating deeply into the lungs (case of lady R.).

When there is regurgitation through the pulmonic valves, a murmur accompanies the second sound. Its nature and diagnosis are the same, (the necessary inversions being made,) an in the case of aortic regurgitation, (p. 366,) except that the pulse is not jerking (case of Rogers. A tremor attended).

I presume that purring tremor with the first sound may be occasioned by contraction of the pulmonic office, though I may not met with instance verified after death: but I have met with three in which the tremor attended dilatation of the pulmonary artery (Weatherly, Bowden, and miss L. P. ------r). A purring tremor occasioned by the pulmonic valves, would be more readily felt than one occasioned by the aortic valves, because it would probably be transmitted as far as the space between the second and third ribs, (where it is out of the cover of the sternum,) provided the patient lay in the horizontal position, and inclined to the left side.

Disease of the pulmonic valves is so rare, that it ought never to be suspected unless the signs described are perfectly well marked, or unless there be patescence of the foramen ovale, or some other communication between the two sides of the heart, - states which experience has proved to be generally accompanied with contraction of the orifice in question.

James Hope, "Signs of Disease in the Pulmonic Valves", in "Treatise on the Diseases of the Heart", Philadelphia 1842.

The nymph, Echo, who was a hypnotic and brilliant conversationalist, was given the task by Zeus, to distract his wife Hera, with her charming conversation, in order for him to carry on his incessant womanizing behind her back. But Hera discovered this ruse and became so angry with Echo she put a terrible curse on her so that thereafter poor Echo was never able to talk to anyone, except to repeat back whatever was said to her. Sometime later, Echo fell desperately in love with the arrogant Narcissus, but unable to tell him her true feelings, only managed to aggravate him by her constant parroting of his own words. Narcissus most cruelly rejected her. Echo was so distressed that she hid away, from all society, in the mountains, where she sadly languished, devoid of any companionship. Gradually her body faded away, and her bones turned to stone, and all that was left of her was her voice, which would continue to echo the words of whatever travellers happened to pass by.

In 1842, James Hope wrote, "Disease of the pulmonic valves is so rare, that it ought never to be suspected" and he gave an expert description on how to diagnose the condition. This lesion was difficult to diagnose, not only because it was mostly unsuspected on account of its rarity - but also on account of its fainter "echoing" of the far more common aortic stenosis. Fortunately in the 21st century we have a remarkable device within which resides the spirit of the tragic Echo, upon whom Hera cast her terrible spell! The echocardiograph captures her voice and speaks to us from her lonely mountainous refuge.

VALVULAR HEART DISEASE PULMONARY STENOSIS

Introduction

Pulmonary stenosis (PS) is a rare condition.

It is rarely affected by acquired disease and most cases are seen in pediatric age groups as a congenital problem.

Natural History

Except for critical stenosis in neonates, survival is the rule in congenital PS.

The long-term course of patients with mild PS is usually benign. It does not tend to progress in severity.

However, untreated severe PS may result in outflow obstruction that does progresses over a period of years despite body growth, and will require intervention within 10 years of diagnosis.

Pathology

Pulmonary stenosis can result in raised right ventricular pressures and consequent right ventricular hypertrophy. If right ventricular failure develops, right atrial pressure will rise and this may result in reopening of the foramen ovale, leading to a shunting of unoxygenated venous blood into the left atrium, and systemic cyanosis.

In less severe cases, right sided congestive heart failure occurs.

An associated defect such as a patent ductus arteriosus may partially compensate for the obstruction by shunting blood from the aorta back into to the pulmonary artery and hence into the lungs.

Causes

- An isolated congenital condition.
- As part of more complex congenital cardiac problem, such as Tetralogy of Fallot.
- *Subvalvular* PS may also occur as a narrowing of the infundibular or subinfundibular region, often with a normal pulmonic valve. This condition can be associated with a ventricular septal defect.

Complications

1. Infective endocarditis.

2. With longstanding untreated severe obstruction, Tricuspid Regurgitation and Right Heart failure may occur.

3. Sudden death is very unusual with pulmonary stenosis.

Clinical Features

Symptoms

Although the diagnosis is usually first made in childhood, symptoms are unusual in children or adolescents with pulmonary valve stenosis even when severe.

Adults with long-standing severe obstruction may have dyspnea and fatigue secondary to an inability to increase cardiac output adequately with exercise.

Signs

1. Pulse:
   - May be reduced in severe cases.
2. Blood pressure:
   - May be reduced in severe cases.
3. Palpation:
   - Right ventricular heave where there is RV hypertrophy
   - Thrill may be detected over the pulmonary valve in severe cases
4. Heart sounds:
   - Murmur mat be preceded by an ejection click
5. Murmur:
   - Harsh systolic ejection murmur maximal at 2nd left intercostal space.
   - Murmur is increased by inspiration.

Investigations

CXR

Check for:

- Cardiomegaly.

- Calcified pulmonary valve.

ECG

- Check for signs of RHV and strain.
- RAD

Echocardiography

This will confirm the diagnosis and assess severity.

The pulmonary valve area of a healthy adult is 2.0 cm2/m2 of body surface area.

- **Mild** valvular PS is defined by a valve area larger than 1 cm^2 and a peak transvalvular gradient of less than 50 mm Hg.
- **Moderately** severe PS occurs if the valve area is 0.5-1.0 cm^2, with a peak transvalvular gradient between 50 and 75 mm Hg.
- **Severe** PS is defined by a valve area smaller than 0.5 cm^2 and a peak transvalvular gradient of greater than 75 mm Hg.

Coronary angiography:

Coronary angiography is indicated in selected cases to detect associated coronary artery disease when surgery is planned.

Knowledge of coronary anatomy improves risk-stratification and determines whether coronary revascularization is indicated in association with valvular surgery.

Management

1. Medical Therapy:
    - Diuretics may alleviate the symptoms of right heart failure.
2. Antibiotic prophylaxis for surgical procedures is no longer recommended (see latest edition of Antibiotic Guidelines)

> "Antibiotic prophylaxis is recommended in patients with the following cardiac conditions if undergoing a specified dental (see Table 2.13) or other procedure (see Table 2.14, Table 2.15, Box 2.4):
>
> - prosthetic cardiac valve or prosthetic material used for cardiac valve repair
> - previous infective endocarditis
> - congenital heart disease but only if it involves:

        - unrepaired cyanotic defects, including palliative shunts and conduits
        - completely repaired defects with prosthetic material or devices, whether placed by surgery or catheter intervention, during the first 6 months after the procedure (after which the prosthetic material is likely to have been endothelialised)
        - repaired defects with residual defects at or adjacent to the site of a prosthetic patch or device (which inhibit endothelialisation)
    - cardiac transplantation with the subsequent development of cardiac valvulopathy
    - rheumatic heart disease in Indigenous Australians only."

3. Surgical Therapy:

- Balloon valvuloplasty is the preferred option provided the valve is relatively compliant and mobile.

  The decision to perform this will be based primarily on the patients symptoms, and on hemodynamic parameters.

- Those with severe valvular fibrocalcific thickening are more likely to require a surgical approach.

Appendix 1

Grading of the loudness of murmurs:

Grade 1 *Very soft, requires an experienced listener*.

Grade 2 *Soft.*

Grade 3 *Moderate and without a thrill*

Grade 4 *Loud with thrill just palpable.*

Grade 5 *Very loud and thrill easily palpable.*

Grade 6 *Very loud, may be heard without the aid of a stethoscope.*

Appendix 2

Auscultatory regions of the heart:

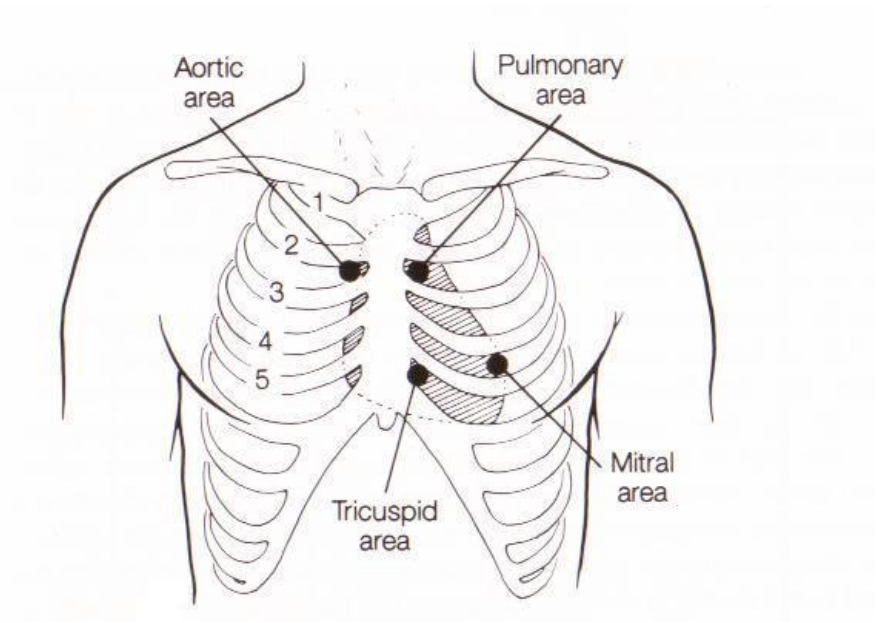

Note, these regions show the optimal areas for listening to the heart valve indicated, they do not exactly correlate with surface anatomy of the anatomical location of the valve.

Appendix 3

The JVP wave form:

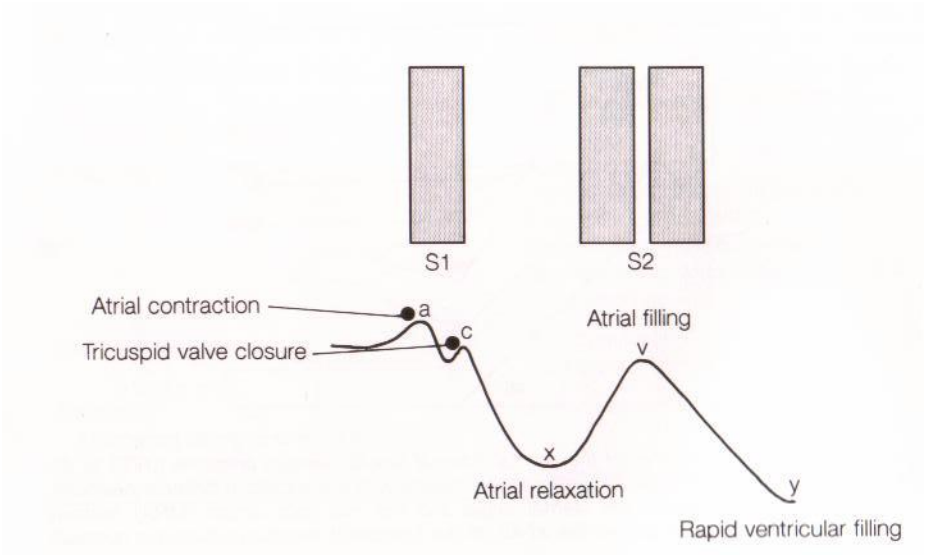

Components of the jugular venous pressure wave with relationships to the first and second heart sounds.

References

1. ACC/AHA Valvular Hear Disease Guidelines: 2008 Focused Update Incorporated September 23, 2008:e1-142. JACC Vol. 52, No. 13, 2008

2. Talley N.J, Clinical Examination 3rd ed 1996.

Dr. J.Hayes
Reviewed July 2013.