THE NORTHERN HOSPITAL

TROPONIN

"Ghost of the Future!" he exclaimed, "I fear you more than any spectre I have seen"

"The Ghost of Christmas Future", illustration by John Leech, First edition of "A Christmas Carol", Charles Dickens, December 1843.

"…and lifting up his eyes, beheld a solemn Phantom, draped and hooded, coming, like a mist along the ground, towards him.

The Phantom slowly, gravely, silently, approached. When it came near him, Scrooge bent down upon his knee; for in the very air through which this Spirit moved it seemed to scatter gloom and mystery. It was shrouded in a deep black garment, which concealed its head, its face, its form, and left nothing of it visible save one outstretched hand. But for this it would have been difficult to detach its figure from the night, and separate it from the darkness by which it was surrounded. He felt that it was tall and stately when it came beside him, and that its mysterious presence filled him with a solemn dread. He knew no more, for the Spirit neither spoke nor moved.

"I am in the presence of the Ghost of Christmas Yet To Come?" said Scrooge.

The Spirit answered not, but pointed onward with its hand.

"You are about to show me shadows of the things that have not happened, but will happen in the time before us," Scrooge pursued. "Is that so, Spirit?"

The upper portion of the garment was contracted for an instant in its folds, as if the Spirit had inclined its head. That was the only answer he received. Although well used to ghostly company by this time, Scrooge feared the silent shape so much that his legs trembled beneath him, and he found that he could hardly stand when he prepared to follow it. The Spirit paused a moment, as observing his condition, and giving him time to recover.

But Scrooge was all the worse for this. It thrilled him with a vague uncertain horror, to know that behind the dusky shroud, there were ghostly eyes intently fixed upon him, while he, though he stretched his own to the utmost, could see nothing but a spectral hand and one great heap of black.

"Ghost of the Future!" he exclaimed, "I fear you more than any spectre I have seen. But as I know your purpose is to do me good, and as I hope to live to be another man from what I was, I am prepared to bear you company, and do it with a thankful heart. Will you not speak to me?"

It gave him no reply. The hand was pointed straight before them….

…..Am I that man who lay upon the bed?" he cried, upon his knees.

The finger pointed from the grave to him, and back again.

"No, Spirit! Oh no, no!" The finger still was there.

"Spirit!" he cried, tight clutching at its robe, "hear me! I am not the man I was. I will not be the man I must have been but for this intercourse. Why show me this, if I am past all hope!"

For the first time the hand appeared to shake.

"Good Spirit," he pursued, as down upon the ground he fell before it: "Your nature intercedes for me, and pities me. Assure me that I yet may change these shadows you have shown me, by an altered life!" The kind hand trembled.

"I will honour Christmas in my heart, and try to keep it all the year. I will live in the Past, the Present, and the Future. The Spirits of all Three shall strive within me. I will not shut out the lessons that they teach. Oh, tell me I may sponge away the writing on this stone!" In his agony, he caught the spectral hand. It sought to free itself, but he was strong in his entreaty, and detained it. The Spirit, stronger yet, repulsed him.

Holding up his hands in a last prayer to have his fate reversed, he saw an alteration in the Phantom's hood and dress. It shrunk, collapsed, and dwindled down into a bedpost. Yes! and the bedpost was his own. The bed was his own, the room was his own. Best and happiest of all, the Time before him was his own, to make amends in!

"I will live in the Past, the Present, and the Future!" Scrooge repeated, as he scrambled out of bed.

"The Spirits of all Three shall strive within me. Oh Jacob Marley! Heaven, and the Christmas Time be praised for this! I say it on my knees, old Jacob; on my knees!" He was so fluttered and so glowing with his good intentions, that his broken voice would scarcely answer to his call. He had been sobbing violently in his conflict with the Spirit, and his face was wet with tears…

"I don't know what to do!" cried Scrooge, laughing and crying in the same breath; and making a perfect Laocoön of himself with his stockings. "I am as light as a feather, I am as happy as an angel, I am as merry as a schoolboy. I am as giddy as a drunken man. A merry Christmas to everybody! A happy New Year to all the world. Hallo here! Whoop! Hallo!"

A Christmas Carol, Charles Dickens, 1843.

On Christmas Eve the old miser Ebenezer Scrooge is visited in his sleep by the Ghosts of Christmas Past and Present. They show him the joy and happiness that Christmas brings to all. He remains unconvinced, and unmoved… "Humbug" he yells! But a terrible vision awaits him from the third Ghost. The grim reaper, as the "Ghost of Christmases yet to be", shows Scrooge the sad fate that awaits him. He is to die, alone, without anyone to mourn him or to even say a kind word about him. In terror he begs the ghostly "spectre" for a second chance. Despite the fact that he does not deserve it, he is granted it. Scrooge is elated and mends his sad and sorry ways.

Like the "Ghost of Christmases yet to come", the grim spectre of an elevated troponin level is a portent of a possible terrible fate. Like the grim Reaper we have the ability to offer many of our patients a second chance. Our patients in return however must promise to lead an "altered life" by doing all in their power to reduce their cardiovascular risk factors. By so doing they may be granted many more happy Christmases yet to come.

TROPONIN

Introduction

Cardiac troponins are the most sensitive and the most specific test for myocardial necrosis.

Cardiac troponins also have prognostic significance particularly in patients with acute coronary syndrome.

Cardiac troponins are now the standard biomarker for myocardial injury.

Older biomarkers such as CK, CKMB, AST and LDH have now, to a greater or lesser extent, been rendered obsolete as a standard for the diagnosis of myocardial infarction.

Physiology

Troponin is a complex of three regulatory proteins that are integral to muscle contraction in skeletal and cardiac muscle, but not smooth muscle.

The 3 subtypes are:

- Troponin I (TnI)
- Troponin T (TnT).
- Troponin C (TnC).

The genes that code for the skeletal and cardiac isoforms of TnC are identical and thus, no structural difference exists between them.

Skeletal TnI and TnT however are structurally different from myocardial TnI and TnT, and immunoassays have been designed to differentiate between them.

No cross-reactivity occurs between skeletal and cardiac TnI and TnT with current assays.

This explains the unique cardiospecificity of the cardiac troponins.

Normal Values

At Northern Hospital **troponin I** is tested for.

The normal value for troponin I at the Northern lab is: **< 0.04 micrograms/L.**

Indications for Testing

Testing for troponin levels should not be indiscriminate, if there are no particular clinical indications to do so.

The predominant indication will be the investigation of the patient with a **suspected acute coronary syndrome.**

A second increasingly used indication is the detection of right ventricular strain, in the setting of large acute pulmonary embolism.

Causes of an Elevated Troponin

1. **Myocardial infarction, (necrosis):**

    - STEMI
    - Non-STEMI

    This is the predominant and most important cause.

Other possible causes include:

2. Pulmonary embolism.

    - Usually a larger pulmonary embolism.

3. Peri/ myocarditis.

4. Heart failure, (including cardiomyopathies):

    - *Acute* heart failure.
    - *Severe* chronic heart failure.

5. Tachyarrhythmias.

6. Cardiac devices:

    - Pacemakers, AICDs

7. Myocardial trauma:

    - Direct contusions.
    - Cardiac surgery

8. Electrocution

    - Including defibrillation, cardioversion.

Non primary cardiac causes:

The cause of troponin elevation in these cases is uncertain, but may represent secondary myocardial injury in the case of shock.

9. Shock:

   - Septic shock or severe sepsis.
   - Severe hypovolemic shock.

10. Subarachnoid hemorrhage (SAH):

    - This is possibly via a neurogenic form of myocardial injury. [2]

11. **Renal failure.**

Causes of a false positive elevated troponin:

The causes of a genuinely false positive troponin result are rare, but may include:

- Heterophile antibodies:

  These are non-specific antibodies that have wide ranging cross reactivity. They cause interference with troponin assays. The source of these antibodies is uncertain, but may include, prior exposure to microbial antigens, foreign animal proteins or auto-immune diseases such as rheumatoid arthritis.

  The lab may be able to counter the effects of these, if they are suspected.

- Technical/ equipment malfunction.

Time course of troponin elevation and decline

It is important to realise that cardiac troponins are *not early* biomarkers of myocardial necrosis.

A time frame of at least 8-12 hours is required before a troponin rise may be seen following an acute coronary syndrome infarction event.

It is for this reason that a period of observation of 8-12 hours since the onset of symptoms will be required to confidently rule out a significant infarction event.

Elevated troponin levels may persist for 7-10 days following an acute coronary syndrome event.

Interpretation of Troponin Results

In the setting of acute coronary syndrome:

Cardiac troponin elevations indicate the presence but not the mechanism of myocardial injury and myocardial damage can occur from a variety of mechanisms *other than* acute ischemia. It is for this reason that the clinical context is also important when interpreting the meaning of an elevated troponin level.

It should be noted that in the clinical setting of an acute coronary syndrome, intervention with a reperfusion strategy such as thrombolysis or PCI is based upon **clinical symptoms** and/or **ST segment elevation on ECG** and that these interventions should *not wait* for an elevation in troponin levels to occur, as these may be significantly delayed.

Further troponin level rises *in isolation* are not an indication for coronary reperfusion intervention.

What an elevation in troponin level means in the clinical context of an acute coronary syndrome, is that the event is **high risk for an adverse outcome**. **These patients are therefore admitted into hospital for further observation, investigation and treatment as required.**

Again in general terms, treatment may be more aggressive, with the addition of anticoagulation for example in high risk patients.

In clinical settings other than acute coronary syndrome:

Elevated cardiac troponin levels in general also predict worse clinical outcomes in conditions other than acute coronary syndromes, especially for large PE and in the longer term for patients with heart failure or renal failure.

It is also associated with a poorer outcome in the setting of SAH. [2]

Disposition considerations:

In a clear clinical presentation of acute coronary syndrome, admission will be required.

Minor elevations in other clinical settings or indeed when the clinical setting is uncertain, are more problematic when formulating a disposition plan.

In these cases a period of observation with serial ECGs and repeat troponin level testing will be required. The diagnosis may eventually become clearer during this period of observation, however if it does not, then cardiology referral may be appropriate.

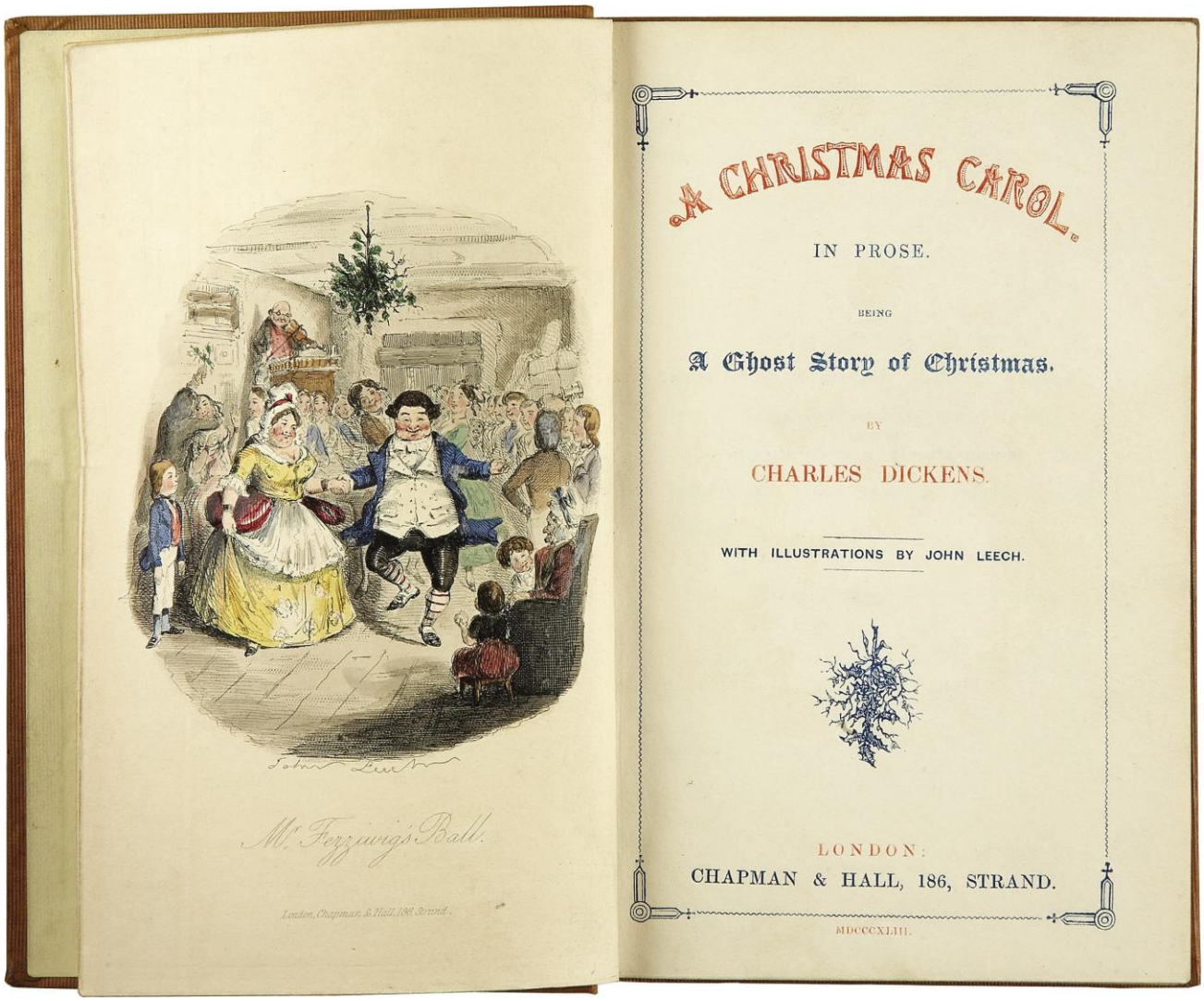

Title Page, First Edition, "A Christmas Carol", by Charles Dickens, Chapman and Hall, London, December 1843.

References

1. Chanwit R. et al. Common Causes of Troponin Elevations in the Absence of Acute Myocardial Infarction, Incidence and Clinical Significance. CHEST 2004; 125:1877–1884)

2. Naidech AM et al, Cardiac Troponin Elevation, Cardiovascular Morbidity, and Outcome After Subarachnoid Hemorrhage. (*Circulation*. 2005; 112:2851-2856.)

Dr J. Hayes
18 October 2008