THE NORTHERN HOSPITAL

TRAPEZOID FRACTURE

"Young Hare" Albrecht Durer, Watercolor and gouache on paper, 1502

".. Some of the fixed stars have tails. And for this we need not rely only on the evidence of the Egyptians who say they have observed it; we have observed it also ourselves. For one of the stars in the thigh of the Dog had a tail, though a dim one: if you looked hard at it the light would become dim, but to less intent glance it was brighter".

Aristotle, Meteorologica, Book I Chapter 6, 325 BC

Aristotle's commentaries on the stars in his "Meteorologica" written in the Fourth Century BC is thought by many astronomers to include the first written description of the deep sky object known as Messier 41, or more simply M41, sometimes today also affectionately designated as "Aristotle's Cluster". To the naked eye it is a barely visible open star cluster, within the constellation of Canis Major, the great hunting dog of Orion. It lies an unimaginable 2,300 light years from the Earth. This cluster is very difficult to see with the naked eye in the 21st Century due to the light pollution given off by the mega-metropolises of the current age. In the Fourth Century BC however, the spectacle of the firmament was vastly superior to the pale vista we observe today from the cities. Even so it required sharp powers of observation to recognize M41.

According to Aristotle it was well known to the Egyptians. His description of it is not only remarkable as the first historical record we have of the cluster, it is also remarkable from a medical perspective as the first description we have of the differing special abilities of the retina to distinguish certain types of images. The peripheral vision consists predominantly of rod cells most sensitive to the perception of shades and night vision. The central vision on the other hand consists primarily of cone cells, most sensitive to colour and sharp images in bright daylight. Stars that are very faint in consequence may not be seen when observed directly by the human eye, however when the periphery of the vision is used to look at the same region of the night sky, by turning the head to one side, these faints stars can in fact be readily perceived out of the "corner of the eye". Aristotle was the first in history to record this phenomenon when he described the strange misty smudge of light in the constellation of Canis Major. He wrote in his Meteorologica… "For one of the stars in the thigh of the Dog had a tail, though a dim one: if you looked hard at it the light would become dim, but to less intent glance it was brighter".

Greek astronomy at the time of Aristotle had built steadily on the works of previous astronomers of the civilizations of the Egyptians, Sumerians and the Babylonians before them. Knowledge of astronomy advanced steadily until its European apogee in the time of the great Ptolemy in the first century AD. So great was Ptolemy's contributions and influence that little further progress in Astronomy was thought possible in the West at that time. With the fall of the Western Roman Empire in 475 AD, the understanding of astronomy not only ceased, it regressed, and as the centuries progressed it was virtually lost in its entirety during a time that history has come to label the "Dark Ages". This noble science would not arise and progress again in Europe for over a millennium, not until the time of the brilliant Polish astronomer Copernicus.

Indeed the study of Astronomy would not have been resurrected so astonishingly quickly, if it were not for the miraculous fact of the preservation of the foundation work of the ancient Greeks, Egyptians and Babylonians. This preservation was not through any agency of the West. When historians talk of the "Dark Ages", they largely refer to the European continent. The preservation of the ancient scientific knowledge of humanity totally unbeknown to the West was held by what they perceived to be a savage and uncivilized culture that suddenly exploded out of the Arabian dessert in the late Seventh Century. Often blamed by the West for the destruction of the great Alexandrian library, the repository of all the accumulated centuries of ancient philosophy and science, this culture on the contrary became the custodians of it. The cause of demise of the great library of Alexandria is by no means clear; it seems simply to have gradually disappeared from recorded history. The vast knowledge it contained seems more likely to

have been embraced by the new culture, rather than destroyed by it. Its works were translated into Arabic and miraculously preserved for humanity, if not at Alexandria, then at Baghdad, Damascus and Cairo. For close to half a millennium unknown to the West the ancient wisdom was preserved in a supposedly barbaric culture, until in the late Tenth century in the monasteries of Sicily the ancient works began to be translated from Arabic back into Greek and Italian, marking one of the most remarkable cultural revolutions in history, known as the European Renaissance.

In the Islamic world, the Seventh to Tenth centuries were not "Dark" at all. Indeed with respect to the sciences they were centuries of "shining light". The age of the Arabian Nights produced the legend of Aladdin's Lamp. To the West the lamp contained the all powerful genie that would grant them any wish. That genie was none other than the West's own preserved knowledge from antiquity, bottled up and hidden for centuries. Yet it was even then more than that. It was the ancient knowledge yes, but even further enriched and progressed by the centuries it had been in the possession of the Islamic world. Once the genie had been "let out of the bottle" by the monks of Sicily it would be the West that would be granted the wish of miraculous possibilities that would come to fruition in the scientific Enlightenment that would follow the Renaissance. The genie was then lost to the Islamic world, just as the West had lost it in 475 AD.

In no other field of the sciences that were preserved by the Islamic culture was there greater progress than in the noble field of Astronomy. Many of the stars today still bear witness to this fact in their names, Fomalhaut, Alnitak, Achernar, Aldebaran, Hadar, Saiph, Vega and a great many others, all Arabic names. In the clear desert skies at night unpolluted by modern city lights, wondrous sights both great and small were studied in minute detail. At the feet of the brilliant stars of Orion, there lies an innocuous constellation only just visible by means of Aristotle's "peripheral vision" a small trapezoid of stars. To the Arabs this was an asterism of four camels drinking quietly from an oasis in the desert. As knowledge in the West was regained from the distant past, it was recognized that these stars were in fact part of the ancient Ptolemaic constellation of Lepus the Hare. A famous sketch by the German Renaissance artist Albrecht Durer in 1502 is of a hare. It is unlike any depiction of any animal that had ever gone before it in respect of its scientific accuracy. Durer's humble Hare is one of the iconic images of scientific observation of the precision of detail of the natural world that has come to symbolize the revolution in thinking in the West that came with the possession of the "genie of Aladdin's lamp".

When we examine a radiograph of the injured wrist, of our patients, we would do well to recall the image of the Hare, for hidden among the brilliant "constellation" of the more recognizable bones of the wrist lies a small and innocuous "trapezoid" often overlooked. We should recall the minute attention to detail of the early Arabian astronomers, as well as that of the great Albrecht Durer. It will only be by this means that an injury to the trapezoid will be detected. When not seen but suspected, we may require a new way of seeing, rather than the "corner of our eye" however, in the 21st century we may do this by means of the miraculous inventions of the CT or MRI scanner, both legacies of the "genie of the lamp".

TRAPEZOID FRACTURE

Introduction

Trapezoid fracture in isolation is very rare.

It is the least commonly injured carpal bone, involved in less than one per cent of carpal injuries. There are very few case reports of isolated fracture of this bone. It is usually fractured in *association* with other injuries.

Plain radiography may not diagnose the injury, and **CT scan** or **MRI** will usually be needed to make the diagnosis.

Anatomy

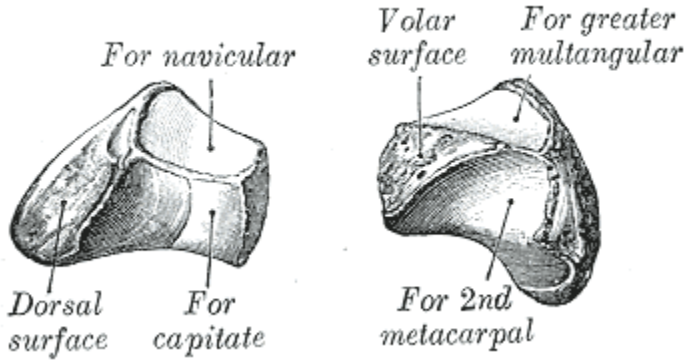

The left trapezoid bone, (the "greater multangular, refers to the trapezium, and the navicular refers to the scaphoid bone), (Gray's Anatomy, 1918)

The trapezoid forms a very stable, relatively immobile joint with the second metacarpal base distally.

The trapezoid is shaped like a keystone and is bound by strong ligaments to the trapezium radially, the capitate on its ulna aspect, and the scaphoid proximally.

Mechanism

The mechanism of injury is axial loading along the line of the second metacarpal.

Complications

Complications may include:

- Secondary degenerative osteoarthritic changes, **these can be chronic and debilitating if the injury is missed.**

- Osteomyelitis in cases of compound injury

Clinical features

The area of maximal tenderness will lie dorsally and ventrally at the base of the second metatarsal.

Investigations

Plain radiography

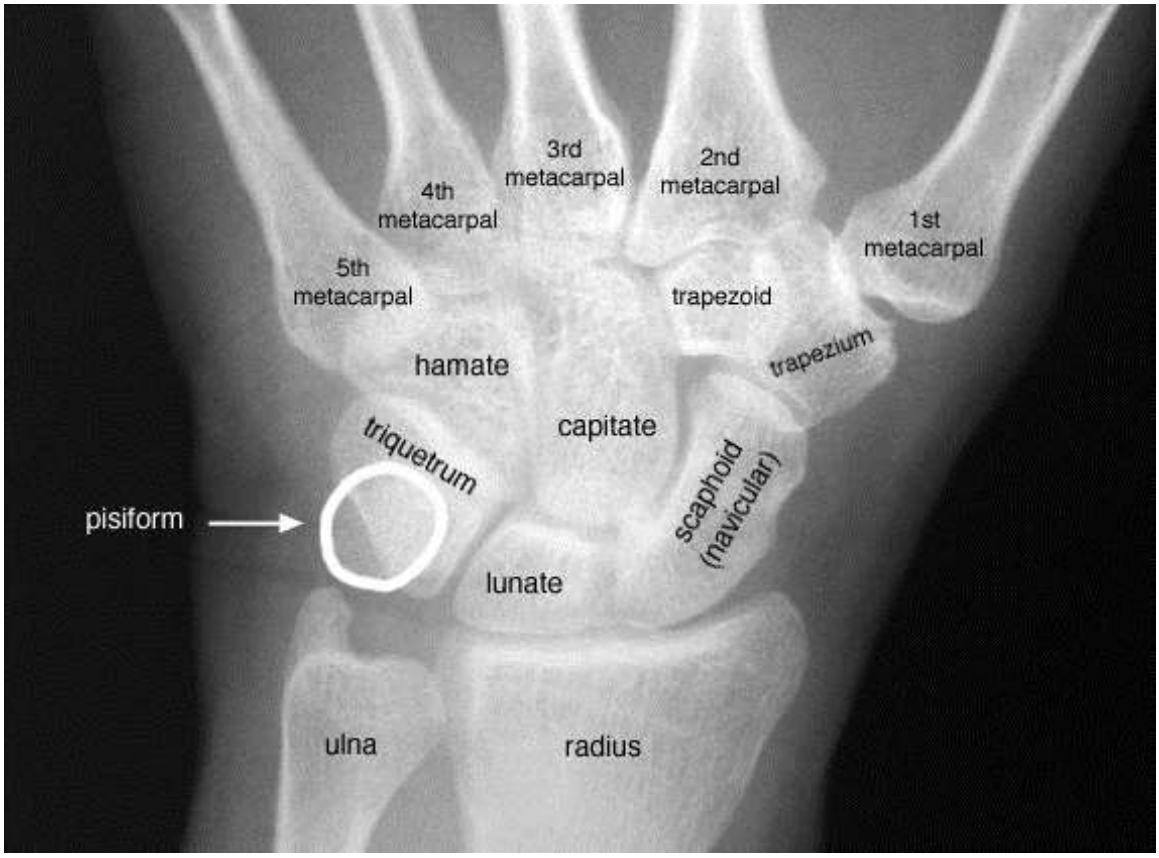

Above, normal A-P radiograph of the left carpus. The trapezoid lies adjacent to its similarly named neighbour the Trapezium with which it articulates on the lateral aspect.

Views should include:

- A-P
- Lateral
- Ulna deviation.
- Trapezium, **trapezoid**, pisiform, and hamate fractures may also benefit from additional carpal tunnel views.

Fracture of the trapezoid is difficult to detect on plain radiography however, and further imaging with either CT or MRI will be needed to confirm the diagnosis in most cases.

CT scan

The trapezium, trapezoid, pisiform, and hamate bones will frequently require an additional CT scan when the plain radiography is unclear and/ or the extent of injury needs to be more fully assessed, particularly in more complex injuries.

MRI

MRI is also useful for imaging the carpal bones in cases where plain radiography is inconclusive yet clinical suspicion remains high.

Management

1. Give analgesia as clinically indicated.

2. Since little has been written on the treatment of trapezoid fractures, a standard treatment method for trapezoid fractures has not been established. [1]

3. **All cases should be referred to the Orthopaedic unit.**

4. Lesser non-displaced injuries are suitable for simple plaster or orthotic immobilization.

   - The period of immobilization will depend on the degree of injury, (2-6 weeks).

   - Minor avulsion type injuries may only require 1-2 weeks, for comfort measures.

5. More severe or displaced injuries will require ORIF.

   Good long term results have been achieved with ORIF. [1]

The constellation of Lepus, the Hare, from the Southern hemisphere. Its dim outline is highlighted here against the brilliant stars of the constellation of Orion. The "trapezoid" is formed by the four faint stars, Alpha, Beta, Gamma and Delta Leporis in the "chest" of the Hare, in the upper right of the constellation.

<u>*References*</u>

1. Hitora T. Isolated trapezoid fracture: A rare case of carpal injury. Injury Extra, Vol 36, Issue 9, September 2005, p. 402-404.

Dr. J. Hayes
Reviewed 19 February 2015.