THE NORTHERN HOSPITAL

TIBIAL SHAFT FRACTURE

Hercynian Forest at Night, (source unknown)

"...wolves were prowling about the camp and howling just before his death... a sound as of women lamenting was heard; and there were shooting stars in the sky..."

Cassius Dio, Book 55 Historia Romana, 3rd Century A.D

On a freezing winter night, in a miserable God forsaken swamp, deep inside the dark Hercynian forest, Nero Claudius Drusus Germanicus, Rome's greatest general, stepson of the Emperor Augustus and brother of the future Emperor Tiberius lay dying in a fevered delirium of unimaginable agony. His last conscious vision on Earth was a stunning night sky - above the bare tree tops he could see the vast cosmos of eternity - shooting stars streaked across the heavens, accompanied by the fearful and haunting howls of the last creatures of the Ice Age.

In 9 B.C, Rome was at its very peak of aggressive expansion by bloody conquest. Operating in the farthest reaches of the frozen North, Germanicus had led his legions almost to the Elbe River near modern day Denmark. This was the farthest north Rome's reach would ever be felt. Germanicus was extremely popular with his troops, they would follow him to the very edge of the Earth, and indeed it seemed as if this is precisely where he had led them. He was Rome's greatest general, since the time of Julius Caesar. No matter how numerous or how fierce the enemy tribes were in his path, all eventually fell before the might of Imperial Rome - then disaster struck!

Germanicus, racing through the dense forest fell from his horse. Ancient sources are conflicting and unclear, but it seems he had sustained a horrific fracture of his leg, quite possibly compound, for very quickly gangrene set in. For weeks he lay in agony unable to be moved, many miles from Rome, at the frozen edge of the known world. He died, Cassius Dio tells us, on a night of shooting stars, and the primal howling of wolves.

In the 21st century, a fracture of the tibia, remains a significant injury, but not one from which death is the expected result. A sophisticated "chain of survival" ensures that the sufferer of this injury is swiftly transported to a modern medical facility within minutes. In the First Century B.C, however the world was an unimaginably different place. A fractured leg was generally survivable, but when compound and sustained in a distant place in an age without mechanized transport, or anaesthesia or antibiotics or a modern understanding of medicine, the outcome would almost certainly be death, and a lingering and most unpleasant one at that.

"Agrippina Landing at Brundisium with the Ashes of Germanicus", oil on canvas, 1768, Benjamin West.

TIBIAL SHAFT FRACTURE

Introduction

Tibial shaft (diaphysis) fractures in adults are major injuries.

They may also occur with relatively minor force in young toddlers or as stress fracture in athletes.

The following relates to **adult fractures** caused by direct trauma

See separate documents for:

- **Tibial Plateau Fracture, (in Orthopaedics folder).**
- **Tibial Triplane Fracture, (in young adolescents), (in Orthopaedics folder).**
- **Toddler's Fracture, (in young children), (in Orthopaedics folder).**
- **Compartment Syndromes, (in Orthopaedics folder).**

Mechanism

Tibial shaft fractures usually occur as a result of:

- A **high energy direct** trauma.
- A torsional injury:
    - ♥ Spiral fractures can when the body rotates around a fixed foot on the ground (e.g. with skiers).

Exceptions to this are:

- **Toddler's fracture**, which is a spiral fracture that occurs with relatively minor trauma in young children who are learning to walk. It usually has the appearance of a fine non displaced "hairline" type fracture of the distal tibia. It is not a recognized injury of child abuse.
- **Stress fractures** - the tibia is prone to stress fractures in athletes.

Classification

Tibial shaft fractures can be technically classified according to the **"AO" system** as follows:

Type A (Simple):

1. Spiral

2. Oblique (angle > 30^0).

3. Transverse (angle < 30^0).

Type B (Multi-fragment wedge):

1. Spiral wedge

2. Bending wedge

3. Fragmented wedge

Type C (Multi-fragment wedge):

1. Spiral wedge

2. Segmental

3. Irregular

More importantly however, the following **descriptors** should be recorded/ communicated:

1. Open versus closed

2. Proximal, mid or distal.

3. Transverse, oblique, spiral, of comminuted.

4. Angulation:

   - Recorded as the distal fragment, in relation to the proximal fragment, in degrees and direction (i.e. anterior/posterior/ varus/valgus).

5. Degree of displacement and/ or rotation.

6. Any associated involvement of the fibula.

7. Any associated **joint** involvement.

Complications

1. Neurovascular compromise:

   - This will be the most immediate and urgent complication.

2. Compartment syndrome:

   Due to the degree of force required to fracture the tibial shaft there is often a high degree of associated soft tissue injury.

There is therefore a significant risk of compartment syndrome of the relatively restricted lower limb fascial compartments, with the attendant risks of neurovascular compromise and rhabdomyolysis.

Indeed tibial shaft fractures are the commonest cause of compartment syndromes, and the syndrome may occur in up to 20% of cases of closed injuries.

Compartment syndrome can take up to **24 hours** to develop.

Indicators of an impending compartment syndrome include:

Uncasted leg:

- Weakness of muscle action
- Pain on passive movement
- Reduced sensation over the distal nerve territory
- Pulses may still be present (loss of pulses is a **late** sign).
- Compartment pressure > 30 mmHg or within 30 mmHg of the mean arterial pressure.

Casted leg:

- Increasing pain *despite* reduction and casting.

3. Associated bony injury:

   - Tibial shaft fracture is often accompanied by fibula shaft fractures. Neck fractures of the fibulae may be associated with peroneal nerve injury.

4. Compound injury:

   - There is a **high risk** of compound injury with tibial shaft fractures because of the close proximity of bone and skin anterolaterally where muscle mass is absent.
   - Tibial fractures are the commonest open fracture.

5. Fat embolism:

   - This may be seen with long bone fractures.
   - The tibia is less commonly the cause of fat embolism than is femoral shaft or pelvic fractures.

6. Delayed, mal and non-union, (usually distal 1/3):

- Delayed union, nonunion, and malunion may occur.

  Among the long bones, the tibia is the most common site of fracture non-union, (up to 15% suffer malunion or non-union).

  Fractures of the **distal third** of the shaft of the tibia are somewhat prone to delayed union or non-union. This may be due to the fact that the nutrient artery to the tibia (a branch from the posterior tibial artery) is torn at the fracture line, with a consequent reduction in blood flow to the distal fragment. [2]

Clinical Features

1. Pain is usually **severe.**

2. Inability to weight bear

3. Deformity and swelling:

   - May be gross, but if not, look for point tenderness.

4. Assess for any associated injuries:

   - Major force is usually required to fracture the tibia in adults, and so other associated injuries should always be anticipated and ruled out.

     In particular, look for injuries to the ipsilateral, hip, femur, knee, foot, pelvis.

5. Neurovascular injury as for all fractures needs to be ruled out.

   - In particular the peroneal nerve and popliteal artery

6. The injury is not infrequently **compound.**

7. Look for evidence of **compartment syndrome.**

Investigations

Blood tests:

For severe injuries:

1. FBE

2. U&Es/ glucose

3. Group and save or cross match as clinically indicated.

Plain Radiography

Plain radiography will make the diagnosis in most cases.

A-P and lateral views must be taken.

The entire bone including the ankle and knee joints should also be visualized.

CT scan

CT may be necessary in complex tibial plateau or ankle fractures, but is not usually required for tibial shaft fractures.

Further imaging

MRI or Bone scan is sometimes used when a stress type fracture is suspected.

Management

Management of tibial shaft fractures in adults:

1. Analgesia:
    - Pain is usually very severe and titrated IV opioid will usually be necessary.
2. IV fluid recusation:
    - This may be needed in more severe injuries.
3. Initial reduction:
    - Reduce displaced, angulated or rotated fractures in the ED under appropriate procedural sedation
    - If there is neurovascular compromise then **urgent** reduction of the fracture will be required under adequate sedation.
4. Splinting:
    - A plaster back slab should be applied for initial immobilization in 20 % knee flexion.
    - Unlike femoral shaft fracture, Donway splint traction is not required.
5. Elevation:
    - Swelling can be significant, with the potential for compartment syndrome and so elevation is an important aspect of initial first aid treatment.

- If compartment syndrome is suspected, then the tibia is best left at the level of the heart. Elevation is contraindicated in a suspected compartment syndrome because it decreases arterial flow and narrows the arterial - venous pressure gradient.

  In patients with tibial fracture and suspected compartment syndrome, the leg should be immobilised with the ankle in **slight plantar flexion**, which decreases the deep posterior compartment pressure and does not significantly increase the anterior compartment pressure.

6. Compound injuries:

   - These will require **immediate IV antibiotics**, saline irrigation of wound and a sterile covering dressing.

   - Give tetanus immunoprophylaxis as clinically indicated.

7. Reduction:

   - If there is significant deformity, then initial reduction should be done in the ED under appropriate sedation, before referral to the orthopaedic unit.

8. Immobilization:

   Patients should be assessed by the orthopedic unit in the first instance.

   Tibial shaft fractures that are closed may be treated with **above knee cast** immobilization if alignment is good.

   However cast application is often delayed for 3-5 days to allow early swelling to diminish.

   Non-operative management may be suitable for fractures with the following characteristics: [1]

   - Closed

   - *Lower energy* injuries without significant comminution, shortening or displacement:

     - ♥ > 50 % cortical contact

     - ♥ < 5-10 ^{0} of varus/ valgus angulation.

     - ♥ < 10-15 ^{0} of anterior or posterior bowing.

     - ♥ < 5-7 ^{0} of rotation.

     - ♥ < 10-15 mm of shortening.

9. ORIF:

ORIF will be required for:

- Intra-articular fractures, (i.e. involving the knee or ankle joints).
- Displaced fractures.
- Comminuted fractures.
- Compound fractures which will require debridement and irrigation in theatre.

Disposition

Even in those fractures suitable for immobilization without operative intervention the threshold for admission should be low because of the potential for compartment syndrome in tibial shaft fractures.

A period of elevation and close observation will often be necessary.

Appendix 1: *(Anatomy of the right tibia and fibula: Gray's Anatomy 1918)*

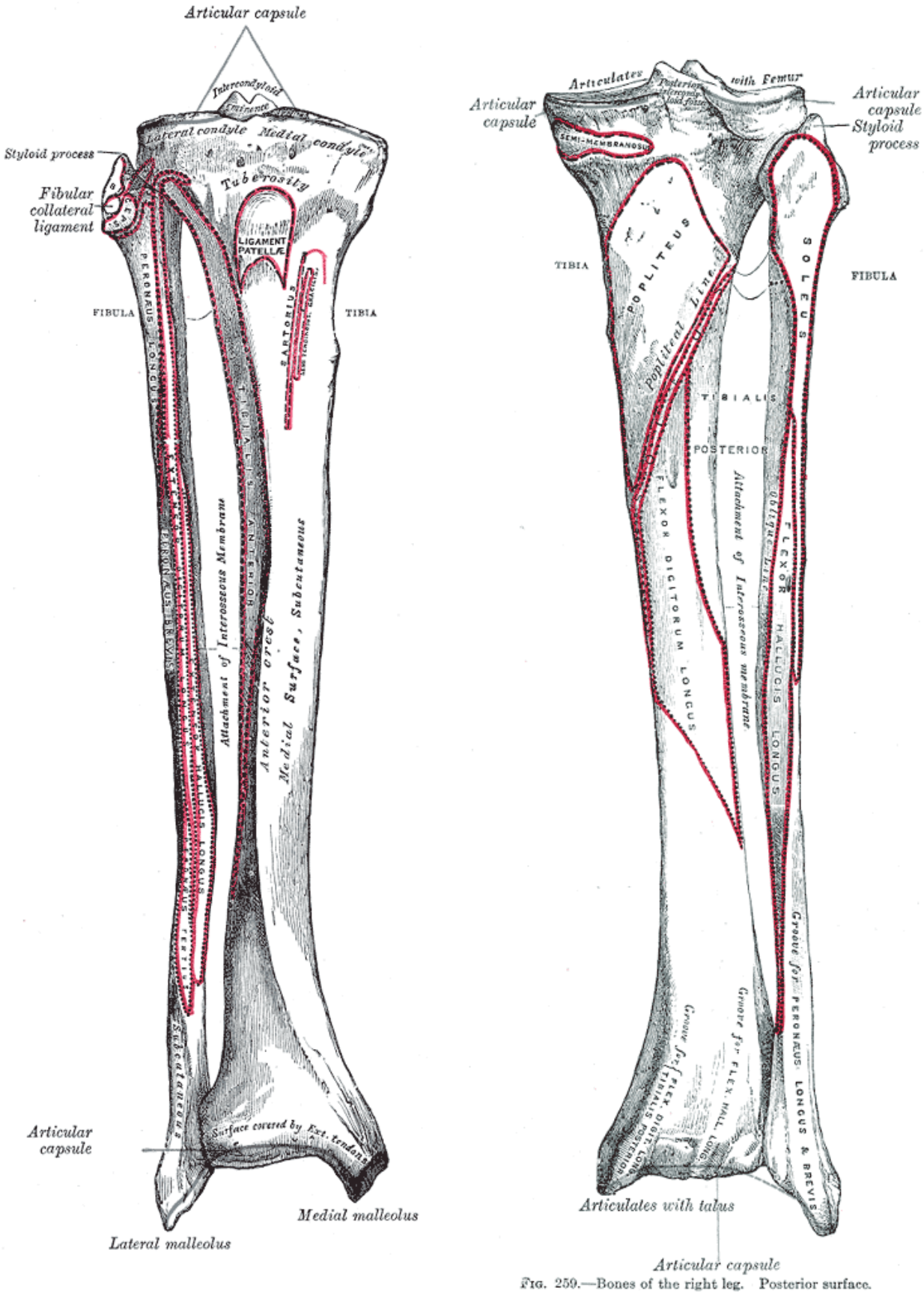

FIG. 259.—Bones of the right leg. Posterior surface.

References

1. M. Baker , M. Cadogan M, Tibia and Fibula Fractures, in Cameron et al, "Textbook of Adult Emergency Medicine", Churchill-Livingston 4th ed, 2015.

2. Snell R. Clinical Anatomy for Medical Students, 5th ed 1995.

Dr J. Hayes
Reviewed October 2015.