THE NORTHERN HOSPITAL

RIB FRACTURES



"The Formation of Eve", Gustave Dore, woodcut print 1865.

"And the Lord God caused a deep sleep to fall upon Adam. And while he was asleep he took one of his ribs, then closed the flesh up again. The Lord God fashioned the rib he had taken from the man into a woman, and then bought her unto the man.

And the man said:

This one at last is bone of my bones
And flesh of my flesh
She is to be called woman
Because she was taken from man."

Genesis 2:21-24.

"The ribs are twelve in number on each side in man and woman, for rarely are only eleven seen, although sometimes I have observed thirteen…The popular belief that man is lacking a rib on one side and that woman has one more rib than man is clearly ridiculous, even though Moses, in the second chapter of Genesis, said that Eve was created by God from one of Adam's ribs"

Andreas Vesalius of Brussels, "De Humani Corporis Fabrica", XIX, 1543.

For one and a half millennia before Vesalius all anatomical knowledge was based on a confused mix of theology and the writings of the Second century Roman physician Galen. Surprisingly, considering the Roman lust for gladiatorial "entertainment", human dissection was largely forbidden and in consequence much of Galen's work was based on animal anatomy and so greatly confused any accurate understanding of human anatomy. Before the humanist age of the Renaissance and the later scientific Enlightenment of the Seventeenth and Eighteenth centuries all medical knowledge was unquestionably based on the teachings of the church and the ancients such as Galen and to question those teachings could result in accusations of heresy with penalties that included torture and horrific execution.

It is little wonder most were unwilling to question the ancients or the church in any way, yet with supreme courage this is exactly what Vesalius did in his landmark book "De Humani Corporis Fabrica" published in 1543. It remains one of the sentinel monuments of Western medicine. Vesalius, a century ahead of his time and in true Enlightened scientific spirit was prepared to put all perceived wisdom aside and start from his own empirical observations gained directly from human dissection. Needless to say he made many new discoveries which often had profound implications for traditional religious and Galenic teachings. A prime example being his accurate description of the ribs. Whilst not directly saying that the Bible was wrong out of fear of the Inquisition, he did imply this was "possible " by disproving the commonly held belief at the time that man had one less rib than woman, an understanding that was directly based on the book of Genesis.

Whenever we assess a patient with fractured ribs we must, like Vesalius, be prepared to look further with an open and questioning mind. Only in this way will we not miss a more profound underlying possibility, such as an associated soft life-threatening tissue injury.

RIB FRACTURES

Introduction

Rib fractures are the most frequently missed fracture following trauma.

Important complications can be considered in terms of the:

1. Immediate:

   - The most immediate life threatening issues with rib fractures will relate to associated underlying soft tissue injuries including:

     ♥ Pneumothorax

     ♥ Hemothorax.

     ♥ Liver / splenic injury.

     It is important that these complications are looked for and excluded.

2. Intermediate:

   - In the intermediate term **pulmonary contusion**, especially with **flail segments**, needs to be anticipated.

3. Longer term:

   - In the somewhat longer term, **pneumonia** will be the predominant problem.

With respect to rib fractures *themselves* **pain** with consequent **hypoventilation** and **impairment of coughing** may lead to atelectasis and stasis pneumonia.

Traditionally rib fractures have been diagnosed on plain radiography with dedicated "rib views". More recently specialized techniques such as dual energy radiology have enhanced the ability of plain radiology to detect fractures.

The "gold standard" imaging modality for rib fractures, however is CT scanning, and current practice now really dictates that trauma patients in most cases are imaged by *CT scanning of the chest and abdomen*, by which means not only can rib fractures be fully delineated, but more importantly the presence of potentially life-threatening underlying soft tissue injuries can also be determined.

As for any trauma the threshold for CT imaging is lowered in those unable to communicate, in cases of high-injury mechanism and in the elderly who are *notoriously* difficult to assess clinically.

See also separate documents on:

- **Flail segments (in Trauma folder)**
- **Pulmonary contusions (in Trauma folder)**

Pathology

Influence of age:

In general younger patients have far more flexible ribs than do adults or the elderly, and in consequence are less likely to suffer fractured ribs. Therefore the presence of multiple rib fractures in young patients implies a relatively greater transfer of force compared to older patients.

It should be noted that rib fractures in **children** are unusual, (they tend to simply bend rather than break) and imply a relatively greater force than that required in an adult. Ribs fractures in children are important in that they may be an indicator of **physical abuse.**

Osteoporosis is common in the elderly., and so bony injuries, including rib fractures may be seen with seemingly minor trauma. The elderly are also more prone to develop delayed hemothorax. The risk of developing complicating pneumonia is also significantly higher in the elderly

Complications

1. Pain/ pneumonia:

    - This will be a significant factor for the patient and many cases will require admission solely for this reason.

      Pain will impair coughing and ventilation and will predispose to **atelectasis** and **pneumonia**

2. Hemothorax

    - This may be due to bleeding from the intercostal vessels, and/or associated soft tissue injury within the chest.

3. Underlying soft tissue injury.

    The most significant injuries will include:

    - Traumatic injury of the aorta.
    - Myocardial contusion
    - Lung injury:

- ♥ Pneumothorax, including “open” pneumothorax.
- ♥ Pulmonary contusion

- Diaphragmatic injury.
- Abdominal organ injury
  - ♥ Hepatic, splenic, renal

4. Flail segments:
   - Impairment of normal respiratory mechanics.
   - Underlying lung contusion.

Classification

When assessing the patient with fractured ribs it is useful to divide the thoracic cage into three regions, upper, middle and lower ribs, as each region is associated with its own particular complications.

Upper ribs (1-3):

- The scapula, humerus, clavicle and their extensive muscle attachments provide some protection to the upper ribs and so fractures of these ribs are an indicator of significant force.
- There is high risk of underlying lung and mediastinal injury, in particular traumatic injury of the aorta.
- These ribs are relatively less important in the mechanics of ventilation.
- They are relatively less mobile than the other ribs and pain is often consequently relatively less of an issue.

Middle ribs (4-9):

- The middle ribs sustain the majority of blunt trauma to the thoracic cage.
- Underlying lung or myocardial contusion may occur.
- There are more significant ventilation problems than in fractures of the upper ribs.
- There is relatively more pain associated with these fractures than those of the upper region.

Lower ribs (10-12):

- The lower ribs are the most mobile
- Underlying lung contusion may occur as well as underlying soft tissue injury to the diaphragm and upper abdominal solid organs, liver, spleen and kidneys.
- There may be significant ventilation problems.
- Pain will be severe and present a major impediment to ventilation.

Clinical Assessment

Important points of history:

1. Mechanism:
    - This is important in raising the index of suspicion, not so much for rib fracture, but for the potential of serious underlying soft tissue injury, TRA in rapid deceleration injuries for example.
2. Co-morbidities:
    - This has important implications for how the patient will respond to injuries received.
    - Significant co-morbidities include chronic heart or lung disease, age and smoking history.
3. Social circumstances:
    - This will have important implications for how a patient will be able to cope with their rib fractures if discharge is being considered.

Important points of examination:

1. **ABC** should be assessed initially as for any trauma.
2. Chest examination:
    - Check for any evidence of **flail segment.**
    - Check for any evidence of **pneumothorax** or **subcutaneous emphysema.**
    - Check for the adequacy of **ventilation**
3. Abdominal examination:

Check for evidence of upper abdominal solid organ injury:

- Tenderness, guarding, rebound, rigidity.

4. Check for **hematuria** suggesting **renal injury** in cases of lower rib injuries.

Investigations

Plain Radiography:

These are useful to:

- Simply document rib fractures (and thus aid in assessing prognosis)
- To rule out associated pneumothorax/ hemothorax (in upright films)

Note that when requesting a CXR to look for rib fractures a specific request needs to be made for *rib views, e.g. right lower or left lower ribs.*

If a rib fracture is not seen on plain x-ray, a fracture is not necessarily excluded, as many will only be picked up on **CT.**

Fractures of the **anterior cartilaginous parts** of ribs will not be seen on plain x-rays, however

See Appendix 2 below.

Duel Energy Subtraction Radiology

This technique is particularly suited to the detection of rib fractures.

Soft tissues shadows can be largely removed and bony structure enhanced.

See Appendix 2 below.

FAST Scan

A bedside **FAST scan** by a skilled operator in a very useful investigation to screen for possible significant underlying soft tissue injury:

1. Myocardial injury:
    - Hypokinetic segments contusion
    - Valve disruption
    - Pericardial fluid (blood)

2. Liver injury

3. Splenic injury

4. Renal Injury

5. Free intra-abdominal fluid.

CT Scan

This is the best imagining modality for the detection of rib fractures. It may also detect fractures through the *costal cartilages* not seen on plain radiography.

Current practice now really dictates that trauma patients in most cases are imaged by CT scanning of the chest and abdomen, by which means not only can rib fractures be fully delineated, but more importantly the presence of potentially life-threatening underlying soft tissue injuries can also be determined.

The main purpose of CT scanning in the setting of rib fractures, include:

1. To fully establish the true *extent* of bony injury.

    - For example if a flail segment is suspected.

2. To assess the presence and degree of associated soft tissue injury:

    - Pneumothorax
    - Hemothorax
    - Pulmonary contusion
    - Traumatic injury of the aorta
    - Abdominal organ injury.

Management

Immediate management in the ED:

ABC issues

As for any multi trauma immediately assess any ABC issues.

With respect to ribs fractures assess for the most serious consequences.

- Pneumothorax

- Flail segments
- Underlying soft tissue injury

Analgesia:

Pain will be the most significant immediate issue for the patient. A number of options are available depending on the severity of the patient's injury and the presence of complicating injuries and co-morbidities.

Options include the following:

1. Oral analgesia
    - This may be al that is required in the first instance for more minor injuries.
2. Parental
    - Opioid analgesia will usually be required for more significant injuries.
3. Nitrous oxide should *not* be used if pneumothorax is present.

If pain is not readily controlled, further options will include:

4. IC nerve blocks:
    - Can use 0.5% marcaine with adrenaline 6-8 hourly.
    - Best for lower ribs, difficult to adequately anesthetise above the 5th rib.
    - Inject at the angle of the rib (about one handbreadth from the midline in adults)
    - 4 mls into each space (can do 4-5 ribs)
    - Some risk of pneumothorax.
5. Pleural catheters:
    - This technique avoids the need for the repeated injections of intercostal nerve blocks (with the attendant increased risk of pneumothorax).
    - It is much less effective in the presence of a significant hemothorax.
    - "Top ups" will be required 6-8 hourly.
6. Serratus Plane Block:

- A newer technique done under ultrasound guidance, can give good multilevel rib and chest wall anesthesia.

7. Thoracic epidurals:

   - Marcaine and/or fentanyl can be given into T8-10. Local spread may reach to T4 (but higher than this level needs to be avoided due to the risk of cardiac nerve involvement)

   - There is good analgesia without significant respiratory depression.

   - The technique, however is technically difficult and there is a risk of inadvertent spinal anaesthesia and the masking of intra-abdominal signs and symptoms.

8. **Patient controlled analgesia devices**:

   - Opioid infusion

   - Ketamine infusion

9. Physiotherapy:

   - Physiotherapy needs to be considered in all patients with rib fractures, whether they are to be admitted or not.

     Note that "strapping" is **not** recommended for rib fractures.

     Mobilization within the limits set by pain is important in order to prevent the complication of stasis pneumonia.

10. Surgery:

    - Surgical fixation of rib fractures may be considered in more extensive injury such as **flail segments** to help control pain and aid in adequate ventilation.

Disposition:

Admission Considerations:

In regard to rib fractures in isolation, these will include:

- Significant pain.

- 3 or more fractured ribs.

- Significant co-morbidities.

- Elderly
- Social issues that may lead to significant problems with a patient's ability to cope with their injury at home.

HDU/ICU:

HDU/ICU referral is recommended for the following groups:

- 3 or more fractured ribs
- Fractured upper ribs (1 -3) (large force required)
- Flail segments
- Underlying pulmonary contusion

Appendix 1

Plain Radiography:

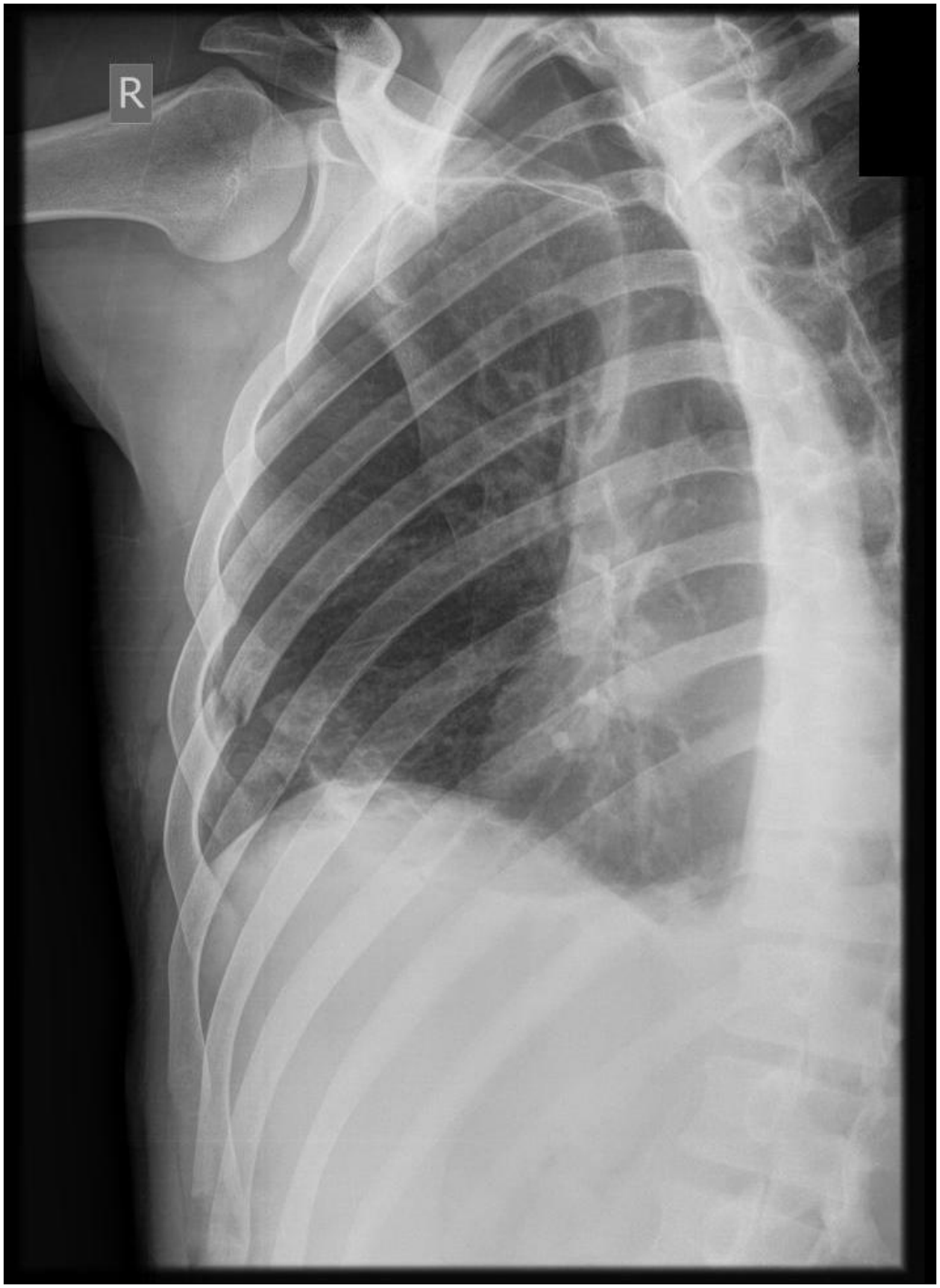

Fractures of the 6th and 7th ribs in a 36 year old male. These fractures are readily seen on ***dedicated oblique rib views****. They may be much more difficult (or impossible) to detect on conventional A-P and lateral chest views.*

Appendix 2

Dual Energy Subtraction Radiology

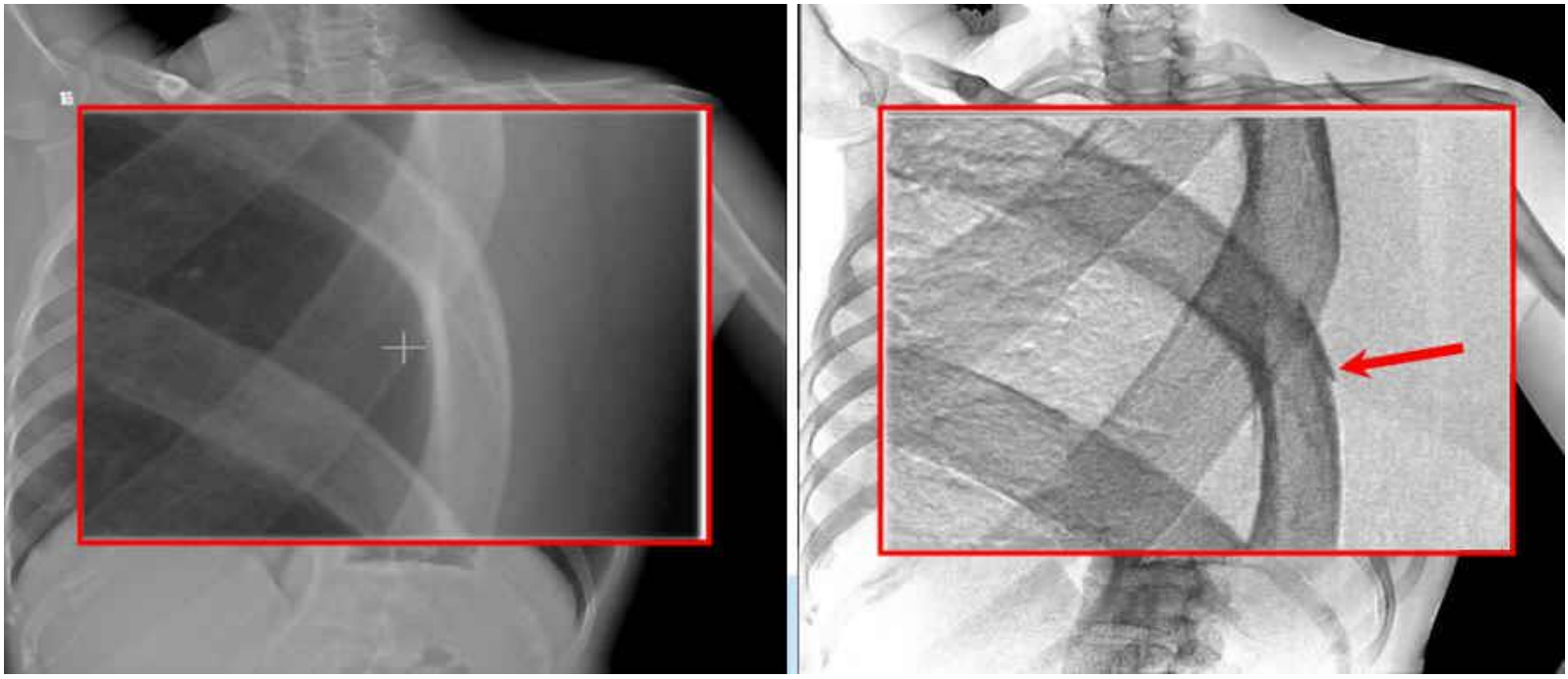

Left: Conventional rib view radiograph. Right: DESR, Bone view, shows a fracture, not apparent on the conventional view.

References:

1. Fitzgerald M, Gocentas. R. Stevens J. Chest Trauma in Textbook of Adult Emergency Medicine, Cameron et al 4th ed 2015.

2. ATLS 10th ed 2017.

Dr J. Hayes
Reviewed 1 August 2018