THE NORTHERN HOSPITAL

PNEUMOBILIA



Left: "L'Instant Taittinger", Vogue Magazine, 1988. Right: Ms Grace Kelly, c.1950.

The experience of the world we live in is a composite result of the sum total of the input of our five senses, sight, touch, smell, taste and sound. In general terms the more senses that are involved in our perception of an event the more intense the experience. To get the best of one's experience of drinking champagne, one savours the sight of the glass, the bubbles, the clarity and the "mousse" (bubby foam at the surface), the sound, with the iconic pop of the cork, the smell of the "bouquet" of the cork and the wine itself, and

of course the taste above all - legend has it that Dom Perignon the blind winemaker of Hautvilliers Abbey in Epernay, who "discovered champagne" when he first tasted his new wine called out in ecstasy "Brothers, brothers come quickly, I am drinking stars!". This leaves us with the final sense of touch. The feel of the cut crystal glass is one thing, but the light touch of the tiny "stars" on our noses as the glass is brought to the lips is really what completes the experience!

The production of the all important bubbles is an art work in itself. The best bubbles are small and float gracefully to the surface. If they are too big, then the champagne becomes too "gassy" and the mousse becomes too thick and unattractive. Louis Bohne, winemaker and agent extraordinaire to the Grande Dame, herself, the widow Clicquot referred to large bubbles as "toad's eyes"! He once exclaimed to her, "I like large eyes everywhere except in champagne wine. May heaven preserve us from their destructive effect!" The large bubble problem of the 1790s was in some part due to letting the wine rest too long in wooden casks in the early stages of production. The finest champagnes are recognized by their small slow rising bubbles. The older vintage champagnes produce these kinds of bubbles and because only the vintage champagnes are aged extensively, small bubbles are associated with the finest quality wines.

An aggravating factor to the large bubble problem was the broad shallow glasses known as "coupes", associated especially with the Golden Age of Hollywood of the 1930s. These glasses in fact had been the standard champagne glass since an Eighteenth century design and the ones that legend held had been modeled on the breasts of Marie Antoinette. But by the later Twentieth century, the stunning "L'Instant Taittinger" campaign changed all of this. The tall elegant figure of Grace Kelly - the original "long cool woman in the black velvet dress" - was used by Claude Taittinger, to promote the Taittinger house. The image of Grace Kelly superimposed on the modern fluted champagne glass, which happily by shear dint of simple physics helped to promote the production of small elegant bubbles - became one of the greatest advertising successes of the twentieth century. Today both the coupes and flute are commonly used for champagne and in truth the size of the bubbles really makes no difference at all to the taste of champagne. As for looks - clarity and mouse - beauty is really just in the eye of the beholder. Many still prefer the coupe glass of the age of Marie Antoinette and La Grande Dame.

When we see air tracts within the shadow of the liver on a plain abdominal radiograph, two patterns can be recognized. The first shows the "bubbles" as if rising within a fluted champagne glass - more narrow and confined. The second shows the "bubbles" settling across a much broader, "mousse" at the top of the hepatic silhouette.

Grace Kelly and James Stewart drink champagne from fluted glasses in "Rear Window, 1954".

PNEUMOBILIA

Introduction

Pneumobilia refers to the presence of air within the biliary tracts.

It is an important radiological sign which has a number of causes ranging from the benign to the life-threatening.

An important radiological differential diagnosis is free gas within the portal veins. This is usually an ominous and late sign indicating ischaemic and necrotic gut.

Pathology

In healthy individuals a normally functioning sphincter of oddi prevents the passage of air from the bowel to the biliary tree, although minor amounts may be seen in the elderly who may have reduced function of the sphincter.

The radiological appearance of air therefore is usually abnormal and should always prompt a carful assessment for its underlying cause.

Causes:

1. Advanced age:
    - Physiologically incompetent sphincter of Oddi
2. Inflammatory:
    - Recurrent/ chronic pancreatitis, with scarring of the sphincter of oddi
    - Biliary-enteric (cholecystoduodenal) fistula.
3. Gallstone related:
    - Recent passage of a gallstone
    - Gallstone ileus.
4. Malignant disease:
    - Cholangiocarcinoma/ ampullary cancer
5. Infective:

    Potentially life-threatening causes here include:

    - Cholangitis (usually in association with choledocholithiasis)

- Emphysematous cholecystitis with gas forming organisms:
    - ♥ Here there is usually gallbladder gas only, but about 20% of cases will also show air within the biliary tree).
- Liver abscess which contains gas and communicate with biliary tree

6. Surgical interventions:

- Recent biliary tract instrumentation:
    - ♥ Post ERCP
    - ♥ Post percutaneous or intraoperative cholangiography (small amounts of air only).
- Surgery involving the biliary tract:
    - ♥ Biliary-enteric surgical anastomosis
    - ♥ Cholecytoenterostomy
    - ♥ Choledochoduodenostomy (with or without bile sump syndrome).
    - ♥ Whipple's procedure
- Surgical damage to the sphincter of Oddi
    - ♥ Post sphincterotomy (approximately 50% have persisting pneumobilia at one year)

Clinical assessment

Important points of history:

Enquire about:

- Any recent biliary tract instrumentation
- Biliary tract surgery
- History of gallstones or pancreatitis
- History of abdominal malignancies

Important points of examination:

1. Vital signs:

    - Fever and / or shock are ominous features, indicating possible cholangitis or emphysematous cholecystitis.

2. Signs of "peritonism":

    - Abdominal tenderness/ guarding/ rebound

Investigations

None may be required, when the cause is known and benign,

When the cause is uncertain the following will need to be considered:

Blood tests:

1. FBE
2. CRP
3. U&Es/ glucose
4. LFTs
5. Lipase
6. Blood cultures
7. ABGs

AXR:

This will usually be the imaging modality that first picks up the presence of pneumobilia.

An important radiological *differential diagnosis* will be free gas within the portal veins.

The appearances are different in that pneumobilia tends to show a gas pattern that radiates from the region of the porta hepatis, branching up into the parenchyma of the liver.

The appearance of portal venous gas however is more usually arranged at along the superior periphery of the liver parenchyma.

A simple mnemonic for remembering the difference in appearance is:

- **P**ortal venous gas → **P**eripheral (*pushed to the periphery*)
- **C**ommon bile duct gas → **C**entral (*central radiation*)

The causes of gas within the portal venous system include:

- Pneumatosis intestinalis.
  - ♥ A relatively benign condition.
- Ischaemic and necrotic gut (from any cause).
  - ♥ **An ominous and late sign in this setting.**

Ultrasound:

This will give valuable information about possible biliary tract obstruction, and / or the presences of gall stones or stone in the bile ducts.

It will also diagnose cholecystitis, including emphysematous cholecystitis, and may indicate pancreatitis

CT Scan:

Abdominal CT scan with **IV contrast,** (but **no** oral contrast) should be requested.

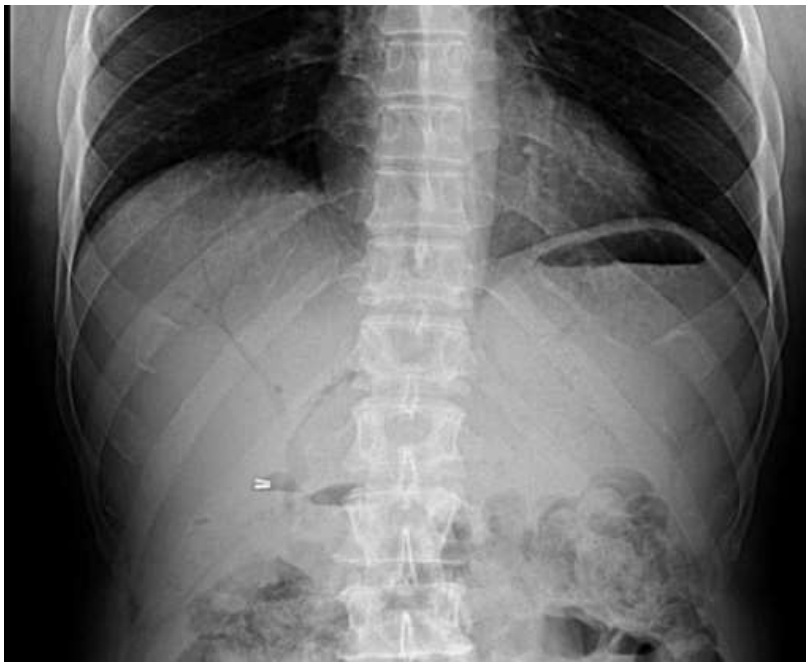

Typical appearance of pneumobilia on plain AXR. Note the streaks of air originating at the region of the porta hepatis and branching from there into the liver parenchyma. In contrast gas within the portal veins concentrates more typically around the superior peripheral margin of the liver, as shown in the CT scan below.

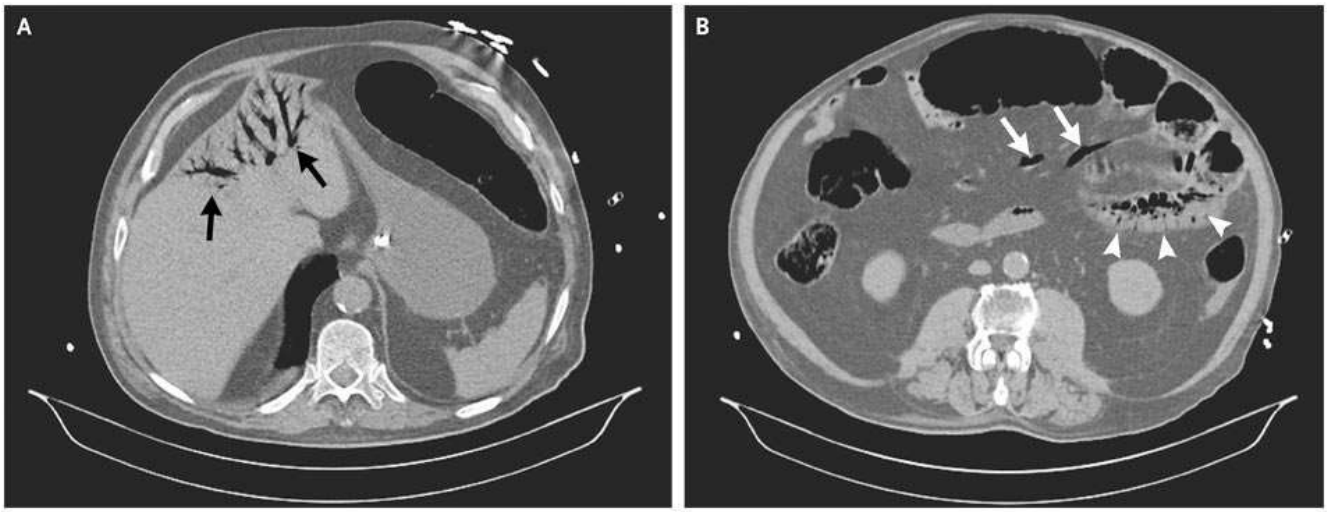

CT of the abdomen showing gas in the intrahepatic portal veins (Panel A, arrows), the superior mesenteric veins (Panel B, arrows), and the jejunal wall (Panel B, arrowheads), all findings strongly suggestive of mesenteric ischaemia. [1]

Management

Pneumobilia is a radiological sign, not a pathological condition in itself, and as such treatment will obviously depend on the underlying cause.

Cut lead crystal coupe style champagne glass, with alternating streaking stars and planets etching, Parisian c. 1860. The left photograph also shows the modern fluted style champagne glass, popularized by Taittinger and the elegant image of Ms Grace Kelly.

<u>*References*</u>

1. Image from Diego de Mendoza-Asensi and Kenneth Planas, in Images in Clinical Medicine, NEJM November 19, 2009

Dr J. Hayes
March 2012