THE NORTHERN HOSPITAL

MESENTERIC ISCHEMIA



"Belvedere", M.C Escher, Lithograph 1958.

This print shows a Belvedere with three stories, seen against a mountainous background. On the floor in the foreground lies a piece of paper on which the edges of a cube are drawn. Small circles indicate the points were two edges intersect. Which of these two lines lies in front of the other depends upon how you look at the cube. The boy sitting on the bench holds in his hands a cuboid puzzle that is a mixture of these two possibilities: its top and its bottom are mutual contradictions.

He broods over it and with good reason, can't believe his eyes. Probably he isn't aware of the building behind him, demonstrating the same impossibility. For instance: the ladder in the center, though correctly drawn according to the rules of perspective and quite acceptable as an object, stands with its base ***inside*** *the house, but* ***outside*** *with its top. Hence the two persons climbing on it are in an impossible relationship to each other.*

M.C Escher, 1958.

The brilliant Dutch graphic artist M.C Escher delighted in tricks of perspective. The columns of the second storey of his "Belvedere" show a third example of the reversed perspective illusion, he so delighted in. Escher had a profound wonder for the "other word" hidden dimensions of space and time. He had a great admiration and drew inspiration from the enigmatic Fifteenth century "surrealist", Hieronymus Bosch, a master of the fantastic and the surreal. The medieval woman at the bottom of the staircase in his lithograph is taken from a tiny detail of Bosch's vision of Hell, a section of his famous "The Garden of Earthly Delights".

When confronted with a work by Escher you will often gain an initial impression of something being "not quite right" and on closer inspection indeed this is the case. Similarly when confronted with an elderly patient in AF who presents with severe abdominal pain, yet their physical signs do not seem right (they are less than would be expected for the degree of distress) a much closer inspection will be necessary. Mesenteric ischemia should be strongly suspected.



Details from (Left) "Belvedere" M.C Escher, and (Right) "The Garden of Earthly Delights" Hieronymus Bosch

MESENTERIC ISCHEMIA

Introduction

Acute mesenteric ischemia is a life-threatening surgical emergency.

It can be difficult to recognize.

The hallmark presentation is the older patient who presents with severe abdominal pain but with abdominal signs that do not appear to correlate with the degree of distress the patient is in.

The condition is usually seen in the elderly, and in particular those with vascular disease and/ or atrial fibrillation.

The outcomes related to the treatment of intestinal ischemia depend largely upon the exact aetiology, as well as time to definitive treatment. Survival of an acute ischemic event is worse for patients with an arterial aetiology compared with a venous aetiology.

For acute mesenteric ischemia, mortality rates are high (around 60 percent).

Terminology:

Ischemia affecting the **small intestine** is generally referred to as **mesenteric ischemia**.

Ischemia affecting the large intestine is generally referred to as colonic ischemia.

A broader term, **splanchnic** (or visceral) ischemia, encompasses ischemia affecting the intestine, as well as other abdominal organs such as the liver, spleen, or kidneys.

Anatomy

The arterial supply to the intestines consists primarily of the **superior mesenteric artery** and **inferior mesenteric artery.**

The venous drainage parallels the arterial circulation and drains into the portal venous system

The superior mesenteric artery supplies the **entire small intestine except for the proximal duodenum.**

The **superior mesenteric artery** and **inferior mesenteric artery** *both* supply the large intestine.

Pathophysiology

Mesenteric ischemia can be divided into acute and subacute/ chronic forms, with the main underlying etiologies being:

1. Acute:

- Superior mesenteric artery occlusion:
  - ♥ Embolus
  - ♥ Thrombus
  - ♥ Aortic dissection
- Superior mesenteric vein occlusion
- Small bowel obstructions
- Non-occlusive mesenteric ischemia (e.g. shock states)
- Small vessel involvement:
  - ♥ Vasculitides (rare)
  - ♥ Chemotherapy-induced enteropathy (possibly ischemic in nature)
  - ♥ Acute radiation enteritis

2. Subacute/ chronic:

- Atherosclerotic stenosis of the superior mesenteric artery (e.g. mesenteric angina)
- Chronic radiation enteritis

Clinical Features

A high index of suspicion is usually required to make this diagnosis as signs and symptoms can be variable and non-specific.

The clinical setting therefore will be important.

Presentations can be:

1. Acute (up to 70 % of cases):

- Presentation is acute and usually dramatic with severe symptoms.
- In **acute** cases there is infarction of (usually) small bowel due to **arterial**:
  - ♥ Embolus, especially from the heart in cases of **A.F** (but also embolism may occur from structural cardiac pathology and from proximal aortic atherosclerotic disease).

- ♥ Thrombosis in combination with atherosclerotic disease.

Less commonly:

- **Venous** infarction can occur:
  - ♥ May be due to hypercoaguable states or from secondary causes (e.g. malignancy or prior abdominal surgery, dehydration).
- **Non-occlusive** low flow states:
  - ♥ Non-occlusive mesenteric ischemia is thought to occur as a result of splanchnic hypoperfusion and vasoconstriction.

    Non-occlusive *colonic* ischemia most commonly affects the "watershed" areas of the colon that have limited collateralization, such as the *splenic flexure* and *rectosigmoid* junction.

2. Subacute:

- There are long periods (months) of relative ischemia, due to a progressive stenosis at the origin of the celiac or superior mesenteric vessels.
- Patients may present with weight loss and fear of eating (due to pain).

3. Chronic:

- This may occasionally occur and will more commonly involve large bowel.
- Ischemia may occur but infarction in this region is uncommon due to the **mixed circulation.**
- The usual feature will be reversible mucosal ischemia.

Once infarction has occurred, perforation, peritonitis septicaemia, and eventually death will follow.

Typical presentations of *acute* mesenteric ischemia include:

Important points of history:

1. There is usually co-existing cardiovascular disease.

- Documented, smoker IHD, PVD, diabetes, hypertension, previous cardiovascular surgery.

- Atrial fibrillation is a common finding, and provides the source of systemic embolism to the gut.

2. Pain:

    - Typically sudden in onset
    - Severity can be variable but will usually be severe.
    - Ill-defined in location / periumbilical

3. Bloody diarrhea:

    - This is classically described, however, it is a **late** sign and its absence does **not** rule out the possibility of mesenteric ischemia.
    - It is more often seen with acute *colonic* ischemia

Important points of examination:

1. Usually occurs in elderly patients.
2. Patients appear unwell, and may be in septic shock.
3. Abdominal signs:

    - There may be few, if any, clinical signs therefore, the condition should be suspected when pain is severe yet signs are surprisingly minimal.
    - Signs will be more prominent if perforation and/ or peritonitis has developed.
    - Ileus may occur.

        ♥ Distended abdomen

        ♥ Absent bowel sounds.

4. PR may show blood.

Investigations

Blood tests:

1. FBE

    - Elevated WCC

2. CRP

    - May be elevated.

3. U&Es and glucose.

   - DKA can be a differential diagnosis.

4. VBGs/ lactate:

   - A lactic acidosis is **often present**, consistent with bowel ischemia.

   - A lactate level can de done, which will correlate with prognosis (rather than aid exact diagnosis).

5. Procoagulation profile:

   - Consider in younger patients without clear risk factors

6. LFTs:

   - Usually normal.

7. Lipase:

   - This should *always* be considered in cases of abdominal pain, where the diagnosis is unclear, in order to help rule out pancreatitis as differential diagnosis.

ECG:

As for any unwell patient.

To document atrial fibrillation.

Plain radiology:

CXR

- Erect CXR to help exclude perforation.

AXR

- May be entirely normal.

- Dilated bowel may be seen indicating an ileus.

Bowel wall abnormalities may include:

- Thickening.

- Thumb printing.

- Air in the gut wall (a *late* sign).

- Portal venous gas:

  - ♥ This is a *very late* sign on plain AXR. It is far better appreciated on CT scan, (see below). It indicates a poor prognosis.

    The vascular gas markings tend to be located at the sub-diaphragmatic periphery of the liver, in distinction to the appearance of gas within the biliary tracts which is usually seen radiating into the liver from the porta hepatis.

CT Angiogram/Venogram

The definitive investigation is a triple phase CT angiogram which consists of:

- **Non-contrast phase**
- **CT arterial contrast phase**
- **CT portal-venous phase contrast (for the uncommon cases of venous infarction)**

Delayed phase can also be done (though not usually necessary) after some minutes.

Oral contrast is **not** necessary and will **significantly delay** diagnosis and management.

CT angiography will more readily demonstrate the recognized indirect plain x-ray findings, as well as document mesenteric vessel clot.

For those with a **significant IV contrast allergy**, a plain CT abdominal scan can still be done, as evidence for ischaemic may still be found, though ischemia cannot be definitively excluded.

See appendix 1 below.

Catheter Angiography:

Although *historically* **catheter** angiography was the gold standard for imaging of suspected intestinal ischaemia CT angiography has replaced it, due to its ability to volumetrically assess the whole abdomen in multiple vascular phases, e.g. arterial, portal venous, delayed.

It also has the added advantage of being able to diagnose **alternative causes** of acute abdominal pain; such as **obstruction, diverticulitis** and **perforation.**

As such CT angiography is now the investigation of choice for patients with suspected intestinal ischaemia.

Direct catheter angiography still has the advantage however of therapeutic interventions such as the administration of intra-arterial thrombolytic agents for acute arterial thrombosis.

Significant disadvantages of catheter angiography are that it is very invasive, not readily available and may significantly delay definitive surgical management.

MRA:

MR angiography is an alternative imaging modality in patients with genuine IV contrast allergy.

It may be more sensitive for the diagnosis of mesenteric venous thrombosis.

Colonoscopy:

This may be required to diagnose colonic (large bowel) ischemia.

Laparotomy:

This may *ultimately* be necessary to establish the diagnosis.

Management

1. Immediate attention to resuscitation issues:
   - IV access
   - Fluid resuscitation as clinically indicated.
2. Analgesia:
   - Titrated IV opioid will usually be required.
3. Nil orally.
4. Nasogastric tube
5. IV antibiotics:
   - Ceftriaxone and metronidazole may be used

   For further alternatives and full prescribing details, see latest edition of Antibiotic Guidelines.
6. Other supportive care as indicated.
7. Specific therapies:

   Options for treatment include:

- Local infusion of vasodilating agents.
- Local infusion of thrombolytic agents:
  - ♥ Usually reserved for patients with a shorter duration of symptoms and without signs of peritonitis.
- Surgery /Laparotomy:
  - ♥ Embolectomy/ surgical resection of ischemic segments of gut.
  - ♥ Arterial bypass/ arterial stenting.

In some elderly patients with severe co-morbidities palliative treatment only may be the most appropriate management.

The treatment of *non-occlusive* mesenteric ischemia focuses on removing causative factors (e.g. vasoconstrictive medications), treating underlying causes (e.g. heart failure, sepsis), hemodynamic support and monitoring, and intra-arterial infusion of vasodilators, if necessary.

Disposition:

1. Urgent Surgical referral:
2. Intensive Care Unit referral:
   - All patients with ischemic gut, who are to have active treatment should be also be referred early to the ICU.

Appendix 1

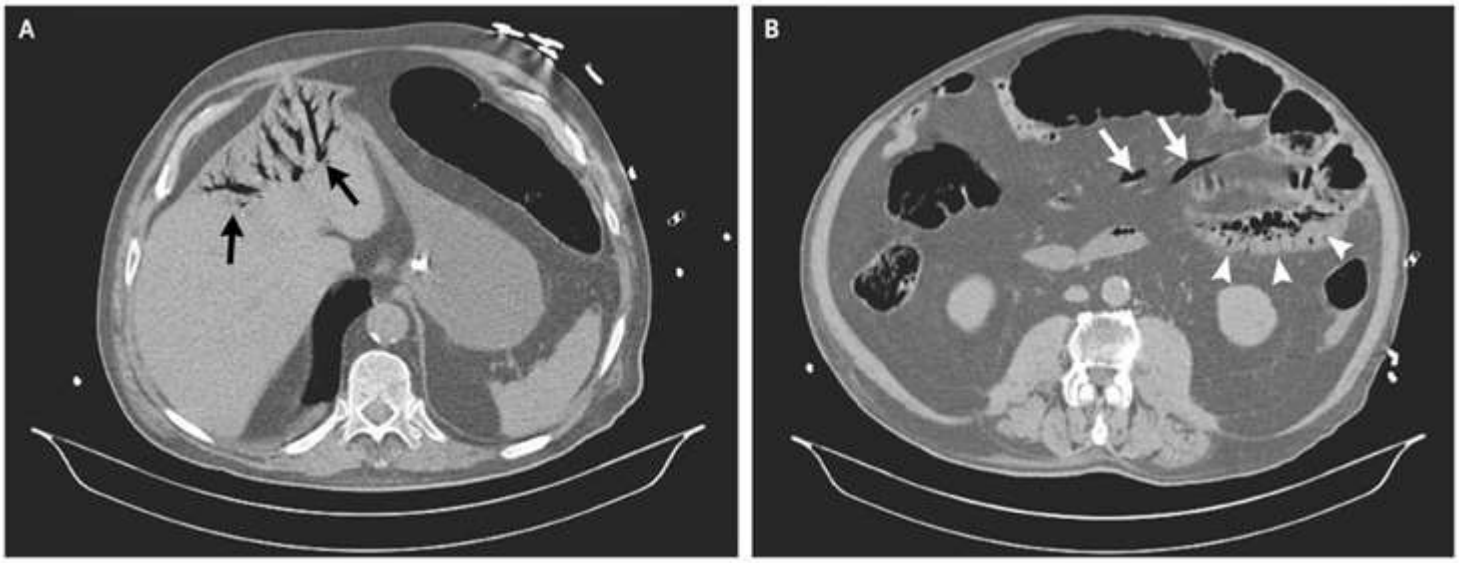

CT of the abdomen showing gas in the intrahepatic portal veins (Panel A, arrows), the superior mesenteric veins (Panel B, arrows), and the jejunal wall (Panel B, arrowheads), all findings strongly suggestive of mesenteric ischemia. [2]

References

1. Peter Grubel, J Thomas Lamont. Overview of intestinal ischemia in adults in Up to Date Website, October 23, 2014.

2. Image from Diego de Mendoza-Asensi and Kenneth Planas, in Images in Clinical Medicine, NEJM November 19, 2009

3. A.Prof Frank Gaillard et al. Intestinal ischaemia in Radiopedia Website:

   - https://radiopaedia.org/

Dr. J. Hayes

Acknowledgements:
Dr. S. Herodotou.
Reviewed April 2017