THE NORTHERN HOSPITAL

KNEE INJURIES (SOFT TISSUE)



"Orchestra Musicians", oil on canvas, 1872, Edgar Degas.

"One only paints what has gripped, and affected one...."

Edgar Degas

The disastrous Franco-Prussian war had just ended. The Paris Commune had been crushed. A semblance of order and peace seemed to have finally come to Paris. A group of avant-garde Artists gathered to catch up with their old colleagues. They agreed that the prospects of getting their works shown at the official Paris Salon, let alone gaining any sort of approval from the Art critics appeared just as bleak as before the outbreak of the recent hostilities. One of the friends, a certain Claude Monet, proposed that the group finance their own exhibition in opposition to the official Salon. All agreed. The little group called itself somewhat dryly, the "Anonymous Association of Artists, Painters, Sculptors, and Engravers", making themselves, as Bernd Growe described, sound more like some sort of business cooperative rather than avant-garde Artists. Their exhibition opened on the Boulevard des Capuchines in April 1874. One critic, Louis Leroy, derisively dismissed the modern works as mere "impressions". The label stuck and history now records the event as the First Impressionist Exhibition. Edgar Degas, being a man of independent means took a lead role in the organization of the exhibition, although the group did not have a formally nominated leader as such. Within the group he insisted on his own independence from the others, always a source of tension and aggravation, although, he made no rebuttal, when lauded by the press as the "leader" of the new "Impressionists". This would lead to accusations, by some, that Degas was always more interested in promoting himself than he was in promoting any new school of Art.

Degas never entirely accepted the label of Impressionist, always considering himself first and foremost a Realist painter. This was realism in the sense of painting modern subjects, capturing the everyday lives of the people of a great metropolis, rather than adhering to the traditional classical, royal or religious motifs prescribed by the Academic, Romantic and Neoclassical schools all of which by this time were rapidly fading genres. There is however no doubt at all, to a modern eye that Degas at least fully embraced the new ***style*** *of Impressionism that gave great creativity to his own particular version of realism. In the early 1870s we see a series of transitional works by Degas, that straddle an earlier age of Realism and the coming age of Impressionism, "Orchestra Musicians", 1872, being a typical example.*

We see Degas seated within the orchestra pit, showing the dynamic action of the musicians. Previous works, had only shown the slightest glimpse of what was actually happening on stage, but in this work, the stage now fully occupies half of the canvas. The style is radically different on stage. We see the brilliant glare of gas-lit iridescent colour and the figures though beautiful are far more indistinct, it's the colour and movement that count here, not the detail - a very Impressionist touch! Degas admitted that he painted only what immediately gripped and affected him. This usually meant the interaction of the audience itself and the musicians rather than what was actually going on, on stage! But by this time a new generation of animated female ballerinas had swept out the tired old Romantic genres, and were gripping all of Paris with their energy and daring! And suddenly these bright young stars gripped Degas' attention as well; we see the moment in "Orchestra Musicians", 1872. Previously we see only the legs of the dancers on stage, though admittedly these were precisely what did grip the attention of

most of the males of the audience much to the outrage of their wives, in an age that for a female to show her leg was considered positively immoral!

The old Romantic Operas had become a thing of the past. Degas was always more interested in the occasion and interaction of the audience, or musicians, but now the actual stage performers have taken his eye. In "Orchestra Musicians", we see for the first time, not just legs, but the entire ballerina. As he sketches away in the orchestra pit. suddenly, the lead dancer meets his eye! Or did she? In fact did she wink at him? It happened so quickly, he couldn't be sure! How can realism capture a fleeting uncertain moment - an impression if you will! He is greatly affected. From this moment and over the next decade, Edgar Degas would paint mostly ballerinas and almost nothing but women. Increasingly he would be drawn into their intimate world of fame, dangerous liaisons, scandal and intrigue. As his realism metamorphosed into impressionism, the musicians and audience would entirely disappear from his canvas, leaving nothing but ephemeral moments of iridescent movement, gesture and colour, that would define the Art of the Belle Epoch. For Degas this genre would be embodied above all else by his beautiful ballerinas.

Edgar Degas in his early career was known as a brilliant young Realist painter, a label he gave himself and never abandoned. Yet today we remember him as one of the greatest Impressionists of the late Nineteenth century. Close examination of his Impressionist works, do indeed reveal vestiges of his early Realism, his genius lay in his ability to meld the two genres into his own unique style. His works record for us a priceless and more perfect vision of life in Belle Epoch Paris, true in its Realism, beautiful in its Impressionism, we not only see this age but we feel it as well!

When we examine a plain radiograph of an injured knee , we must approach it as did Edgar Degas approach his canvas. The immediate realism of the bones are clear to any who have eyes to see; but we must look further for the subtle and more fleeting signs, not at all obvious to a casual observer. In this manner we may see "impressions" of tiny bone fragments, and unusual shadings, and by so doing we will gain a more perfect understanding of what we are seeing!

KNEE INJURIES (SOFT TISSUE)

Introduction

These following describes an overall approach to soft tissue knee injuries that present to the Emergency Department

The main issues in the ED will relate to:

1. Pain relief
2. Clinical assessment
3. Imaging options
4. Disability assessment
5. Disposition planning

The most important soft tissue knees injuries to consider will include:

1. Medical or Lateral collateral ligament injuries
2. Anterior or Posterior cruciate ligament injuries.
3. Medial or Lateral meniscus injuries
4. Knee dislocation
5. Patella dislocation

Of all these conditions the most serious - by far - is **dislocation of the knee,** (not to be confused with *dislocation of the patella*, an entirely different condition!)

Dislocation of the knee, is a true orthopaedic emergency because of the high risk this injury carries with respect to damage to the popliteal artery.

Plain radiography cannot definitely diagnose these injuries, but is still essential to rule out associated bony injury, and may give some important clues to the presence of significant soft tissue injury. **MRI and/ or arthroscopy** are the definitive investigations.

See also separate documents for each of these specific injuries, (in Orthopaedics / Orthopaedics - Sports Injuries folders).

History

The **Segond fracture**, was named in 1879 for the French surgeon **Paul Ferdinand Segond**, (1851-1912) who based his observations on cadaveric experiments.

Pathology

The most important conditions with respect to soft tissue injuries around the knee include:

1. Medical or Lateral collateral ligament injuries

2. Anterior or Posterior cruciate ligament injuries.

3. Medial or Lateral meniscus injuries

4. Knee dislocation

5. Patella dislocation

Of these conditions the most serious is **dislocation of the knee.** This is a **true orthopaedic emergency** because of the high risk this condition carries with respect to damage to the popliteal artery.

Clinical assessment

Important points of history:

1. Mechanism of injury:

   - High energy mechanisms of injury are more likely to result in **serious injury** and more likely to be associated with ***other*** **injuries.**

   - For collateral ligament injuries:

     A valgus or varus force to the knee is likely to cause collateral ligament injury.

     ♥ A valgus force will predispose to a medial collateral ligament injury

     ♥ A varus force will predispose to a lateral collateral ligament injury.

   - A twisting injury is likely to cause a meniscus injury.

     For cruciate ligament injuries:

     Forces likely to result in an **anterior cruciate injury** include:

     ♥ A severe hyper-extension force to the knee

     ♥ A severe *internal* rotation of the tibia in relation to the femur

- For posterior cruciate ligament injuries:

  - ♥ May occur with falls in which the tibia strikes an object and is forced backwards.

  - ♥ May also occur in motor vehicle dashboard injuries whereby the knee strikes the dashboard in head on collisions.

  Note that any significant enough valgus or varus force that injures the collateral ligaments of the knee may also damage the cruciate ligaments.

2. History of problems suggestive of a meniscal injury:

   Meniscus damage is suggested by a history of the **triad** of recurrent:

   - **Clicking**

   - **Locking**

   - **Giving way**

3. Ability to weight-bear after the injury.

4. More severe injuries may *distract* the patient from lesser injuries.

   - Always enquire whether there are any other areas of pain *apart* from the knee.

Important point of examination:

1. Vascular integrity:

   - This is only really an issue in cases of **suspected knee dislocation**, where assessment of the vascular integrity of the lower limb is mandatory.

2. Deformity:

   - Swelling and bruising may be apparent, and the greater these are, the more likely a significant injury is present.

     Note however that the absence of these will not rule out the possibility of a significant soft tissue injury.

   - Cruciate, collateral or meniscus injuries do not typically result in deformity.

- Deformity may be seen with a dislocation of the knee; if not deformity then swelling is at least significant.

- Patella dislocation has a characteristic deformity, but if absent does not rule out the fact that this injury may have occurred, as spontaneous reduction is common.

  Note that inexperienced staff often label a dislocated patella as a "dislocated knee". This is very much incorrect. A dislocated knee is a severe limb threatening injury, whilst a dislocated patella is a mild injury with a good outcome!

3. Tenderness:

   In rough terms:

   - Joint line tenderness suggests a meniscus injury.

   - Maximal tenderness above and below the joint line (in the regions of the insertion of the collateral ligaments) suggest a collateral ligament injury.

4. Joint stability:

   A range of clinical tests are described for the testing of joint stability and major ligament integrity, (see separate documents for these).

   - In practice however these are of limited value in the acute setting, as pain severely limits their proper application and so they are difficult to interpret.

   - What is more important in the Emergency Department assessment will be the degree of **overall pain, swelling** and **disability** that is observed, as well as noting the mechanism of injury.

     It is these factors which will more accurately raise or lower the *index of suspicion* for a significant soft tissue injury around of knee.

5. Locking:

   - A locked knee, (**the inability to fully extend the knee**) is a significant finding.

     This sign suggests a loose foreign body with the knee joint.

     It may also indicate the requirement for admission if this cannot be manipulated within the ED

6. Mobility:

- Patient mobility is an important aspect of the ED assessment.

  This will have implications for subsequent management and disposition considerations.

Investigations

Imaging options include:

1. Plain radiography
2. Ultrasound
3. CT scan
4. MRI
5. Arthroscopy

Plain radiology

Three views are conventionally taken:

- A-P
- Lateral
- Patella ("skyline")

Plain radiographs cannot definitively diagnose a soft tissue knee injury.

However, they are useful in order to:

- **Rule out bony injury**
- **Gain indirect evidence of significant soft tissue injury.**

Decision algorithms exist that assist in the decision to x-ray a knee injury or not - most notably the "**Ottawa Knee Rules**".

In theory these are sound from a scientific point of view, but in practice, can be problematic in busy high-volume Emergency Departments with a *high rate of staff turn-over*, who are unfamiliar with these rules, or are inexperienced in their routine application.

In practice X-rays are simply ordered where any doubt exists to enable staff to quickly move on to the next patient, without fear of missing a fracture, (with the attendant litigation that could go with this!)

Where a clinician does not think an x-ray is required, the Ottawa rules are useful to apply and document, when patient expectation of an x-ray is high! At least in these cases they provide some objective science (and hence medico-legal protection) in a decision **not** to x-ray!

There are a number of important subtle signs that should be looked for on plain x-rays particularly when the radiograph appears normal, that indicate potentially serious occult soft tissue injury.

These include the following:

Lipohaemarthrosis:

Classic example of a lipohaemarthrosis of the knee. The is no obvious fracture seen on this view, though the presence of the lipohaemarthrosis makes a fracture certain.

Lipohaemarthrosis (shown above) is an important soft tissue sign.

It is demonstrated by the fluid level to the right of the patella. It indicates an **occult** facture and the need to further investigate when no fracture is apparent on a plain film.

The superior lucent region represents **medullary fat**, not air, (and hence a fracture must be present), whilst the inferior opacity represents **blood**. (**See also Appendix 1 below**).

Segond's fracture:

This is a small avulsion bone fragment that occurs at the **upper lateral margin** of the **lateral tibial condyle** where ligaments attach.

Surprisingly, the *exact* cause of a Segond fracture continues to be somewhat contentious! The conventional teaching has been that it is the result of avulsion involving the middle third of the lateral capsular ligaments, but there are other candidate structures including the iliotibial band and the anterior oblique band of the fibular collateral ligament.

Whatever the exact ligamentous structure involved the significance of the **Segond fracture** is that despite the seemingly trivial bony injury, there is a very high prevalence of associated internal derangement especially of the **anterior cruciate ligament** and the **menisci** (lateral and medial) and so follow-up **MRI** should be done to look for these injuries.

Segond fracture, of the right knee, (the small bony fragment just lateral to the proximal lateral tibial plateau).

Recognized associated soft tissue injuries associated with the Segond fractures include:

1. ACL tear

   This is the most common associated injury, (75-100 % of cases)

2. Medial or lateral meniscal tears (around 65-75 % of cases)

Less commonly:

3. Avulsion of the ACL from the tibial attachment, (rare)

4. Avulsion of fibular attachment of the long head of biceps femoris

5. Avulsion of the fibular collateral ligament

Reverse Segond fracture:

White arrow showing a Reverse Segond fracture at the medial proximal tibial plateau of the right knee. The black arrow shows another avulsion fragment of the medial tibial eminence suggestive of a posterior cruciate ligament avulsion.

These are small avulsion fractures at the **medial** aspect of the **medial tibial condyle**

They are due to avulsion of the deep fibers of the medial collateral ligament (also known as the menisciotibial or coronary ligament) involving the medial proximal tibia adjacent to the articular surface. It is the opposite of the Segond fracture, which involves the **lateral** proximal tibia.

The reverse Segond fracture is thought to result following external rotation of the knee, with applied valgus stress (compared with the Segond fracture which is thought to result from internal rotation and varus stress).

Unlike the Segond, which is often seen with **sporting injury**, the reverse Segond appears to occur with **higher energy** injuries, such as being struck by a motor vehicle, (and may be associated with knee dislocations, also a high energy injury).

Reverse Segond fractures have a high association with:

1. Disruption of the posterior cruciate ligament

2. Peripheral medial meniscal tears.

Avulsion fractures of the tibial eminence:

These (as shown above) have an association with cruciate ligament injuries.

Avulsion fragments associated with the anterior cruciate ligament may be seen:

- At the anterior tibial spine.

Avulsion fragments associated with the posterior cruciate ligament may be seen:

- At the posterior tibial spine.

Ultrasound

This has limited value in acute soft tissue injuries of the knee

It can detect joint fluid and may give an indication as to whether this is reactive synovial fluid or blood, but will not usually alter management or negate the need for more definitive investigation. It is also somewhat "operator dependent".

It is more useful for associated **muscle** or **tendon injuries** around the knee rather than meniscal or ligamentous injuries.

CT scan

This is an excellent imaging modality for the detection of bony fractures

It may be required when clinical uncertainty remains in the presence of an apparently normal plain x-ray, or it may be required to more fully delineate an injury detected on plain radiography.

It is indicated when plain x-rays fail to show a bony fracture, but other clinical or radiographic signs suggest an occult injury.

MRI

This is by far the best imaging option for soft tissue injuries of the knee

It is the most sensitive and the most specific imaging modality for the menisci and for the ligaments.

Arthroscopy

Direct arthroscopy is the "gold standard" for imaging the soft tissue structures of the knee, but of course has the draw backs of requiring an anaesthetic and being an invasive procedure.

It has the advantage however of allowing **therapeutic intervention** to take place at the same time as visualization of the soft tissue injury.

Management

Management will of course depend on the exact nature of the underlying injury.

In general terms:

1. RICE:

    - As for any soft tissue injury the RICE (rest, ice, compression and elevation) principle is useful as initial first aid treatment

2. Analgesia is given as clinically indicated.

3. Assessment of functional disability, and any physiotherapy and/ or occupational therapy requirements.

4. Plan for the most appropriate disposition.

Note that knee joint aspiration for large haemarthoses is *not* recommended. There is the risk of introducing infection, for very limited gain, and bleeding is likely to continue in any case until there is more definitive management.

Disposition

Orthopaedic referral:

Urgent orthopaedic referral and admission considerations include:

- **Patients with (or suspected of having had - spontaneous reduction can occur) a dislocated knee.**

  These also require urgent vascular imaging.

- **Large hemarthroses**, (there is likely to be significant internal joint derangement)

- Locking of the knee, that cannot be manipulated free in the ED

- Patients with significant co-morbidities and/ or the elderly who are likely to be unable to cope with their injury.

Discharge from the ED:

Definitive diagnosis is not possible in the ED as this can only be achieved by **MRI** and/ or **arthroscopy.**

The majority of acute soft tissue knee inquires however are of relatively *minor degree* and these can be discharged from the ED to be followed up as outpatients.

Even relatively major injury (apart from a knee dislocation) such as cruciate ligament rupture will not require immediate repair.

Patients who are able to mobilize may usually be discharged with "tubigrip", and crutches, to be reviewed at a later date.

In the majority of cases symptoms will settle over a week, but if they do not then an MRI (or arthroscopy) may be warranted.

Early MRI/ arthroscopy may be warranted for:

- Large hemarthroses

- Locked knee that cannot be successfully manipulated

- Elite athletes

Appendix 1

Lipohaemarthrosis – plain radiograph and CT Scan:

Lipohaemarthrosis (shown above in a 55 year old male who had injured his left knee) is an important soft tissue sign. It is demonstrated by the fluid level below and to the left of the patella. It indicates an occult facture and the need to further investigate when no fracture apparent on a plain film. The superior lucent region represents medullary fat, (hence fracture), whilst the inferior opacity represents blood.

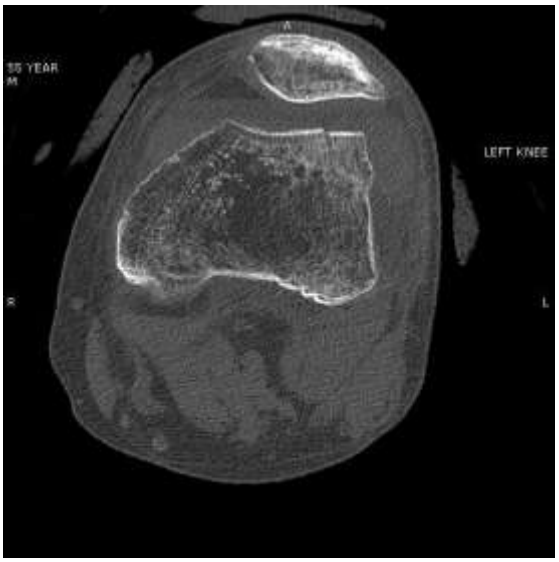

The CT scan on the right shows a subtle fracture of the left lateral femoral condyle, not apparent on plain films.

The lipohaemarthrosis is again seen.

References

1. Escobedo EM et al. The “Reverse Segond” fracture: association with a tear of the posterior cruciate ligament and medial meniscus.

2. For all conditions: Radiopedia Website:

   - https://radiopaedia.org/

Dr J. Hayes
Reviewed March 2017.