THE NORTHERN HOSPITAL

LEFT BUNDLE BRANCH BLOCK

"Anything is better than being alone"; "Heart Break Hotel", oil on canvas,
Jack Vettriano

I hear a lot of stories, I suppose they could be true
All about love and what it can do for you
High is the risk of striking out, the risk of getting hurt
And still I have so much to learn

Well I know 'cause I think about it all the time
I know that real love is hard to find

And a good heart these days is hard to find
True love, the lasting kind
A good heart these days is hard to find
So please be gentle with this heart of mine

My expectations may be high, I blame it on my youth
Soon enough I'll learn the painful truth
I'll face it like a fighter then boast how I've grown
Anything is better than being alone

Well I know 'cause I learn a little every day
I know 'cause I listen when the experts say,

That a good heart these days is hard to find
True love, the lasting kind
A good heart these days is hard to find
So please be gentle with this heart of mine

As I reflect on all my childhood dreams
My ideas of love weren't as foolish as they seemed
If I don't start looking now I'll be left behind
And a good heart these days, is hard to find

I know, it's a dream I'm willing to defend
I know it will be worth it in the end

A good heart these days is hard to find
True love, the lasting kind
A good heart these days is hard to find
So please be gentle with this heart of mine

Feargal Sharkey, "A Good Heart", 1985.

Left bundle branch block (LBBB) can be an significant finding on an ECG. Mostly it will simply represent old and stable pathology, which can be confirmed by examining the patient's past ECGs, when available. However, a ***new*** *LBBB is an important finding. The clinical context is critical when assessing the significance of a LBBB, and it must be borne in mind, that unlike the situation with RBBB, where the finding is frequently an incidental one in an otherwise normal heart, in the case of LBBB, we must listen when the experts say, a* ***good*** *heart is hard to find!*

LEFT BUNDLE BRANCH BLOCK

Introduction

Left bundle branch block (LBBB) is a form of intraventricular conduction abnormality, where there is a failure of conduction through the left bundle branch.

Because the left bundle branch of the conducting system is subdivided into anterior and posterior fascicles, LBBB can be considered a form of **bifascicular block.**

Unlike RBBB, it is unusual for left bundle branch block to exist in the absence of organic disease.

While LBBB itself does not produce any clinical manifestations, it is an important ECG finding in the setting of suspected ACS.

The presence of a LBBB in suspected acute coronary syndrome (ACS) can make assessment difficult.

See also separate documents on:

- **Bifascicular block**
- **ACS - LBBB**

Anatomy

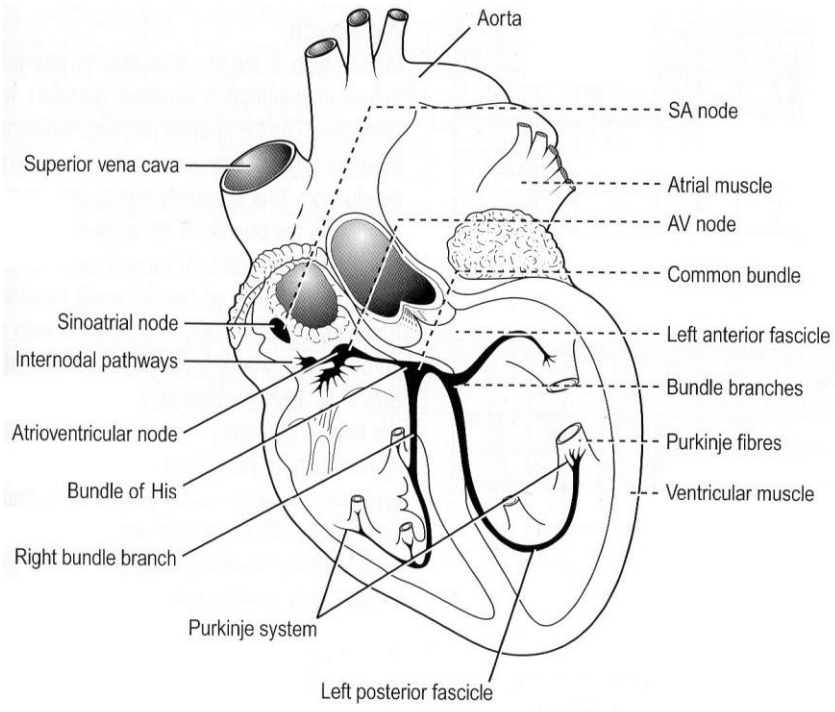

The conducting system of the heart, (Ganong 17th ed, 1995)

Pathology

Normally the septum is activated from left to right, producing small Q waves in the lateral leads.

In LBBB, the normal direction of septal depolarization is reversed (becomes right to left), as the impulse spreads first to the RV via the right bundle branch and then to the LV via the septum.

This sequence of activation extends the QRS duration to > 120 ms and eliminates the normal septal Q waves in the lateral leads.

The overall direction of depolarization (from right to left) produces tall R waves in the lateral leads (I, V5-6) and deep S waves in the right precordial leads (V1-3), and usually leads to left axis deviation.

As the ventricles are activated sequentially (right, then left) rather than simultaneously, this produces a broad or notched ("M"- shaped) R wave in the lateral leads, (and a broad or notched "W" shaped QRS in the antero-septal leads).

Unlike RBBB, it is unusual for left bundle branch block to exist in the absence of organic disease.

Causes

The commonest include:

1. Ischaemic heart disease:
   - ACS/ Myocardial infarction
   - Extensive Coronary Artery Disease
2. Hypertensive heart disease
3. Cardiomyopathy
4. **Cardiac pacemakers** (give a LBBB **morphology**)

Less commonly:

5. Hyperkalaemia, (this may not be a true LBBB – but rather a morphology resembling it)
6. Myocarditis
7. Advanced rheumatic heart disease

8. Primary degenerative conductive tissue diseases

- Lenegere disease (primary degenerative disease of the conduction system)
- Lev disease (sclerosis of the cardiac skeleton)

9. Calcific aortic stenosis

10. Rate related LBBB:

- Tachycardia-dependent BBB:

  Here one of the bundle branches becomes diseased and rather than failing completely (which would produce a fixed bundle branch block pattern), and develops a prolonged refractory period.

  Below a certain rate, this prolonged refractory period has no effect; impulses are conducted normally.

  However above the "critical" rate, the diseased bundle branch is unable to conduct impulses fast enough and a bundle branch pattern appears on the ECG.

  Rate related fascicular blocks (i.e. LAFB, LPFB) may also occur, producing left or right axis deviation respectively when the rate increases above a certain threshold.

- Bradycardia-dependent BBB:

  This is much less common than tachycardia - dependent BBB.

  Here a bundle branch pattern appears whenever the rate falls below a certain rate.

  This happens because of a tendency for damaged cells within the bundle branches to "leak their charge" and become unexcitable when the intervals between impulses are too long.

11. **Rarely**, LBBB is seen in normal, healthy individuals.

LBBB and CVS disease risk

Historically, the presence of a LBBB in ACS has been associated with a higher risk of major adverse cardiac events, including death, MI and stroke.

Current Australian guidelines include new (or presumed new) LBBB in the definition of a STEMI, with recommendation for urgent coronary reperfusion therapy.

However, recent studies suggest that few patients with suspected ACS and LBBB will ultimately be diagnosed with myocardial infarction.

Furthermore, patients with LBBB are more likely to have underlying cardiac risk factors which led to the development of cardiac conduction disease. Therefore, it has been suggested that LBBB may simply be a marker of overall cardiac risk, rather than an independent contributor to morbidity and mortality.

Clinical Assessment

LBBB does not result in any overt clinical symptoms in its own right, the clinical **context** therefore becomes the most important aspect.

It is most significant in the patient who has presented with possible **ACS.**

Patients should therefore have their presenting story carefully evaluated, in addition to a careful evaluation of their **risk factors** for **CVS** disease.

See also Acute Coronary Syndrome - LBBB document.

Investigation

Blood tests

None may be necessary, depending on the clinical scenario, however the following should be considered:

1. FBE
2. U&Es/ glucose
   - In particular **serum potassium**
3. Troponin:
   - In the setting of actual or suspected **ACS**.

ECG

Complete LBBB:

1. QRS widened > **0.12 seconds (> 3 squares),** (complete LBB blocks)
2. V1 (right precordial leads) has a dominant S wave:
   - A **QS** morphology.

Or

- An **rS** morphology.

There may also be notching within the complex (**W-shaped**)

3. V6 (lateral leads) has:

- A **monophasic R** wave (**no septal Q wave** and no S wave) (I & V6)

There may also be a notch within the complex (**M-shaped**)

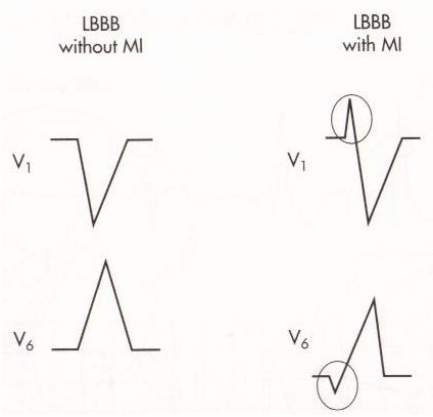

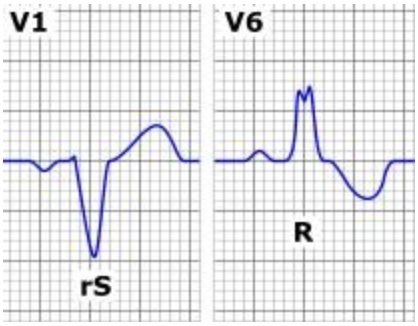

Influence of previous MI on LBBB patterns.

4. ST segment and T wave discordance:

- The ST segments and T wave should be oriented in a vector direction opposite (**discordant**) to the main deflection of the QRS complex.

  This is known as appropriate discordance with bundle branch block. Concordant ST segments may suggest ischemia or myocardial infarction.

5. Left axis deviation may be present

Incomplete LBBB:

- *Incomplete* LBBB looks like "normal" LBBB (i.e. morphological criteria for LBBB are present) but the QRS duration is within normal limits, (i.e. < 0.12 seconds). ST-T wave changes may be less pronounced This is often a progression of LVH.

  Incomplete LBBB may also be termed an **intraventricular conduction delay with a left bundle branch block morphology**

LBBB can be distinguished from LVH by the presence of prominent monophasic R waves and absence of q waves in leads I and V6.

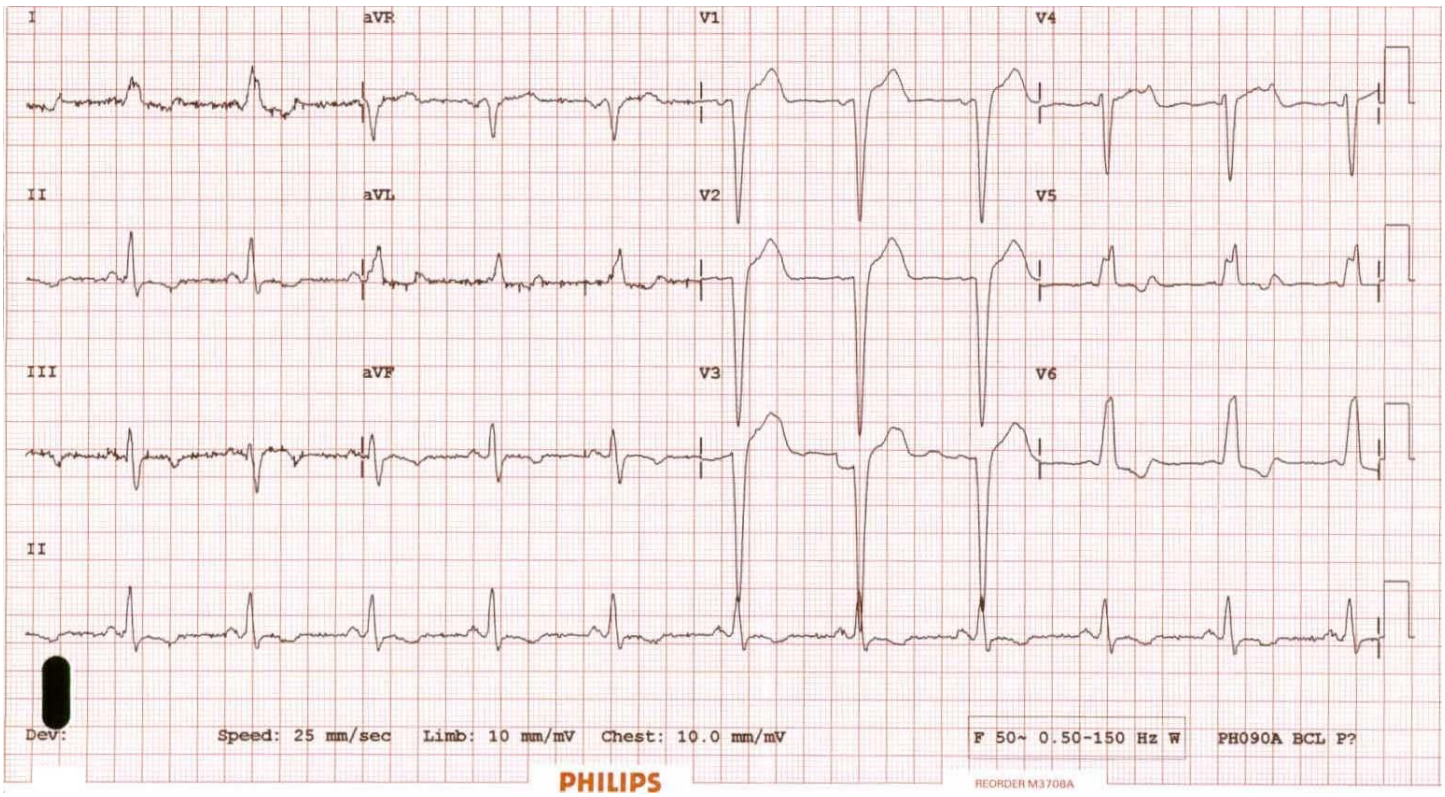

12 lead ECG of a 65 year old male demonstrating the typical features of a LBBB

In the setting of suspected **ACS**, the **Sgarbossa Criteria** can assist in determining the presence of myocardial infarction (**see also ACS - LBBB**).

CXR:

Look for cardiomegaly and/ or signs of cardiac failure.

Management

LBBB of itself does not require specific treatment.

Management of the patient with LBBB will therefore depend on the clinical setting, including:

1 The **underlying cause**, most importantly, has the patient an ACS?

- **See ACS-LBBB document.**

2 Whether the block is acute or chronic

3 Whether the block is intermittent.

References

1. Neeland IJ et al. Evolving Considerations in the Management of Patients with Left Bundle Branch Block and Suspected Myocardial Infarction. J Amer Coll Cardiol. 2012;60:96-105.

2. Rogers R et al. Intraventricular Conduction Abnormalities. *Emerg Med Clin N Am* 2006;24:41-51.

3. Chan JC. ECG in Emergency Medicine and Acute Care 1st ed 2005.

4. Acute Coronary Syndrome Guidelines Working Group. Guidelines for the management of acute coronary syndromes. MJA 2006; 184 (8): S1-S32

Dr J. Hayes
Dr L. Lee

Reviewed 1 September 2016.