THE NORTHERN HOSPITAL

CUTANEOUS LARVA MIGRANS



"Beach Girl", print by Rene Gruau.

Do you remember back in old L.A. (oh oh oh)
When everybody drove a Chevrolet (oh oh oh)
Whatever happened to the boy next door
The sun-tanned crew-cut all-American male

Remember dancin' at the high school hop (oh oh oh)
The dress I ruined with the soda pop (oh oh oh)
I didn't recognize the girl next-door
The beat up sneakers and the pony tail

Beach baby, Beach Baby give me your hand
Give me somethin' that I can remember
Just like before we can walk by the shore in the moonlight
Beach baby, Beach baby there on the sand
From July till the end of September
Surfin' was fun, we'd be out in the sun every day

Mmmm, I never thought that it would end
Oooooh oooooh, mmmm, and I was everybody's friend Ooooh ooooh
Long hot days
Cool sea haze
Jukebox plays
But now it's fading awaaaaay

We couldn't wait for graduation Day oh oh oh
We took my car and drove to San Jose oh oh oh
That's where you told me that you'd wear my ring
I guess you don't remember anything

Beach baby, Beach Baby give me your hand
Give me somethin' that I can remember
Just like before we can walk by the shore in the moonlight
Beach baby, Beach baby there on the sand
From July till the end of September
Surfin' was fun, we'd be out in the sun every day

John Carter, "The First Class", 1974

Ah yes - I remember those olden days! January through to March, (Southern Hemisphere) 1974! I never thought that it would end. Those long hot days, that cool sea haze..... I didn't recognize the girl next door; she certainly gave me something to remember!....but now.....well, sadly it's all just away fading awaaaaay....

But do we perhaps over romanticize our youth somewhat? - the sunburn - out in the sun every day - and then there was that nasty dose of cutaneous larva migrans!? Hell yes - both conditions are quite curable - I'd take both again in the blink of any eye - to go there back there again in July (Northern Hemisphere) - even just for one more day... oh oh oh.!

CUTANEOUS LARVA MIGRANS

Introduction

Cutaneous larva migrans is a parasitic **skin infection** caused by hookworm larvae.

These larvae usually infest cats, dogs and other animals.

Humans can be infected with the larvae by walking barefoot on **sandy beaches** or contacting moist soft soil that have been contaminated with animal faeces.

The condition is also known as the "creeping eruption" as once infected, the larvae migrate under the skin's surface and cause **raised serpiginous erythematous tracks** and physical trauma resulting from **scratching.**

Cutaneous larva migrans is self-limiting.

Humans are an accidental and "dead-end" host so the hookworm larvae eventually die.

The natural duration of the disease varies considerably depending on the species of larvae involved.

In most cases, lesions will resolve without treatment within 4 - 8 weeks.

Epidemiology

The hookworms most commonly involved in cutaneous larva migrans are found in tropical or subtropical geographic locations

Cutaneous larva migrans is particularly seen in:

- The Caribbean
- Central and South America and South Western USA
- Africa
- Southeast Asia.

Beaches are a common source of infection.

Pathology

Organism

Hookworms are nematodes, parasites that live in the small intestine of the host.

There are two species that use **humans** as their hosts:

- Acylostoma duodenale
- Necator americanus

Many other species use animal hosts, but humans be infected through the skin, but then the organism cannot penetrate through the dermis and so humans act as accidental "dead-end" host so animal hookworm larvae which eventually die.

Animal host hookworm species include:

- Ancylostoma braziliense: the most common;
  - ♥ Hosts are wild and domestic dogs and cats; primarily found in central and southern USA, Central and South America and the Caribbean
- Ancylostoma caninum:
  - ♥ Hosts are dogs; primarily found in **Australia.**
- Uncinaria stenocephala:
  - ♥ Hosts are dogs; primarily found in Europe.
- Bunostomum phlebotomum:
  - ♥ Hosts are cattle.

Rarely:

- Ancylostoma tubaeforme:
  - ♥ Hosts are cats.
- Strongyloides papillosus:
  - ♥ Hosts are sheep, goats, and cattle.
- Strongyloides westeri:
  - ♥ Hosts are horses.

Pathogenesis:

On contact with human skin, the larvae can penetrate through **hair follicles, cracks** or **cuts** or **abrasions**, but can even penetrate intact skin to infect the human host.

Between a few days and a few months after the initial infection, the larvae migrate beneath the skin.

In an **animal** host the larvae are able to penetrate the deeper layers of the skin (the dermis) and infect the blood and lymphatic system. Once in the intestine they mature sexually to create more eggs that are then excreted to start the cycle again.

However, in a **human host,** the larvae are **unable** to penetrate the **basement membrane** to invade the dermis so the disease remains **confined to the outer layers of the skin.**

Transmission

- Parasite eggs are passed in the faeces of infested animals to warm, moist, sandy soil, where the larvae hatch.

  On contact with human skin, the larvae can penetrate through hair follicles, cracks or even intact skin to infect the human host.

- Humans normally become infected with the hookworm larvae by:

  - ♥ Walking barefoot on a beach,

  - ♥ Direct contact with soil that is contaminated with animal faeces

Incubation Period

- Between a few days and a few months after the initial infection, the larvae migrate beneath the skin

Reservoir

- The usual hookworm hosts are most commonly cats and dogs but other animals can also be hosts.

Period of Communicability

- Cutaneous larva migrans is not transmitted person to person.

Susceptibility and Resistance

People of all ages, sex and race can be affected by cutaneous larva migrans if they have been exposed to hookworm larvae.

Clinical Features

Ask about recent travel to tropical or subtropical regions.

Typical rash of cutaneous larva migrans, in a 19 year old returned traveller from South East Asia, (photograph courtesy Dr Michelle Van Den Driesen).

Progression of Cutaneous larva migrans in a patient's foot over the course of one week, (photo CDC).

A non-specific eruption occurs at the site of penetration of the hookworm larvae.

There may be a tingling or prickling sensation within 30 minutes of the larvae penetrating.

The larvae can then either lie dormant for weeks or months or immediately begin creeping activity that create 2-3 mm wide, snakelike tracks stretching 3- 4 cm from the penetration site.

These are slightly raised, flesh-coloured or pink lesions that cause intense itching.

Typically there are:

- Raised serpiginous erythematous tracks

And

- Physical trauma resulting from scratching, (i.e scratch marks)

This is due to an allergic immune response to the larvae or its byproducts.

Tracks advance a few millimeters to a few centimeters daily and if many larvae are involved a disorganized series of loops and tortuous tracks may form.

Sites most commonly affected by cutaneous larva migrans include:

- The feet, in particular the web spaces between the toes
- Hands
- Knees
- Buttocks.

Natural history:

Cutaneous larva migrans is self-limiting.

Humans are an accidental and "dead-end" host so the hookworm larvae eventually die.

The natural duration of the disease varies considerably depending on the species of larvae involved.

In most cases, lesions will resolve without treatment within 4 - 8 weeks.

Complications:

1. Secondary skin infection
2. Löffler’s disease:

- This is the combination of pulmonary infiltrates and eosinophilia that can occur with heavy infestations of parasitic larvae.

- It is a generalized sensitization with soluble antigens in the lung that causes the pulmonary infiltrates

Differential diagnosis:

These may include:

- Strongyloides
- Scabies
- Contact dermatitis.
- Dermatophytoses, (Tinea pedis).
- Impetigo

Investigations

Diagnosis is usually clinical.

There is no specific serological testing available for zoonotic hookworm infection

In uncertain cases, skin biopsy ahead of the leading tract may show a larva in a burrow and inflammatory infiltrate

Management

Prevention:

Preventive measures can include:

- Avoiding direct skin contact with contaminated soil or sand; e.g., wearing shoes on the beach, and not sunbathing or sitting directly on sand, by using towels.
- Prohibiting cats and dogs on beaches.
- Deworming of pets.
- Covering sandpits when not in use.

Symptomatic treatment:

Antipruritic agents:

These may also be used with the anthelminthic agents to provide symptomatic relief of itch.

Options include:

- Antihistamines
- Topical corticosteroids

Specific treatment:

Even though the condition is self limiting, symptoms can be significant and so treatment is usually required.

Anthelminthic agents will shorten the duration of illness, clear the lesions and cure pruritis.

1. Anthelmintics agents:

   Effective treatment is available to **shorten the course** of the disease.

   Anthelmintics agents are used, which include:

   - Tiabendazole (topical or oral)
   - Albendazole (oral)
   - Mebedazole (oral)
   - Ivermectin (oral)

   Topical thiabendazole may be used for early localized lesions.

   Oral treatment is given when the cutaneous larva migrans is more widespread or topical treatment has failed.

   Itching is considerably reduced within 24 - 48 hours of starting antihelmintic treatment and within 1 week most lesions/tracts resolved.

3. Antibiotics:

   - Secondary skin infection may require treatment with appropriate antibiotics.

Appendix 1

Hookworm lifecycle:

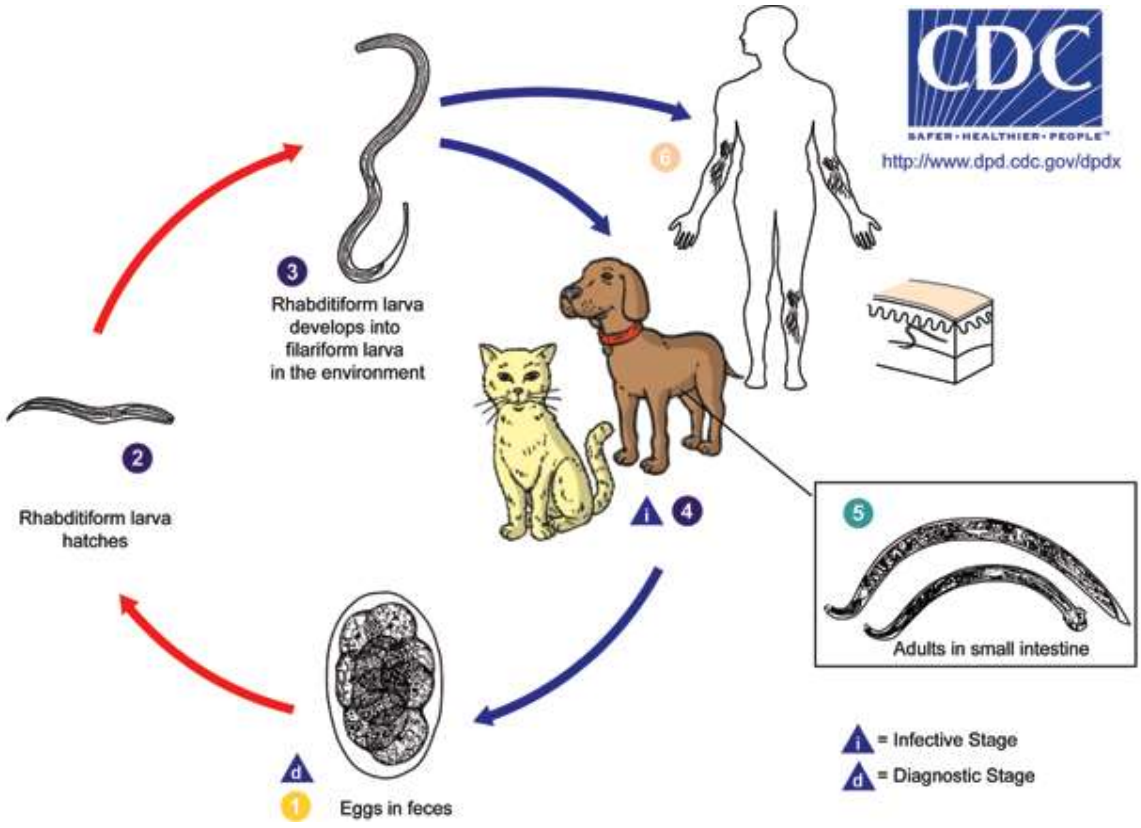

Cutaneous larval migrans (also known as creeping eruption) is a zoonotic infection with hookworm species that do not use humans as a definitive host, the most common being A. braziliense and A. caninum.

The normal definitive hosts for these species are dogs and cats.

The cycle in the definitive host is very similar to the cycle for the human species.

Eggs are passed in the stool (1), and under favorable conditions (moisture, warmth, shade), larvae hatch in 1 to 2 days.

The released rhabditiform larvae grow in the feces and/or the soil (2), and after 5 to 10 days (and two molts) they become filariform (third-stage) larvae that are infective (3)

These infective larvae can survive 3 to 4 weeks in favorable environmental conditions.

On contact with the animal host (4), the larvae penetrate the skin and are carried through the blood vessels to the heart and then to the lungs.

They penetrate into the pulmonary alveoli, ascend the bronchial tree to the pharynx, and are swallowed.

The larvae reach the small intestine, where they reside and mature into adults.

Adult worms live in the lumen of the small intestine, where they attach to the intestinal wall.

Some larvae become arrested in the tissues, and serve as source of infection for pups via transmammary (and possibly transplacental) routes (5).

Humans may also become infected when filariform larvae penetrate the skin (6).

With most species, the larvae cannot mature further in the human host, and migrate aimlessly within the epidermis, sometimes as much as several centimeters a day. Some larvae may persist in deeper tissue after finishing their skin migration.

References

1. DermNet NZ

   - www.dermnetnz.org/

2. CDC Website, accessed December 2014.

3. Lydia A Juzych Cutaneous larva migrans in eMedicine Website, 31 July, 2014.

Dr J. Hayes

Acknowledgements:
Dr Michelle Van Den Driesen.
Reviewed August 2015.