THE NORTHERN HOSPITAL

BUTTON BATTERY INGESTIONS

"Volta presenting the battery to Bonaparte". Fresco, Niccola Cianfanelli, Museo della Specola, c. 1840.

"...A number of pieces of zinc, each the size of half a crown, were prepared, and an equal number of pieces of card cut in the same form, a piece of zinc was then laid upon the table, and upon it half a crown, upon this was placed a piece of card moistened with water, upon the card was laid another piece of zinc, upon that another half a crown, then a wet card, and so alternately until more than forty pieces of each had been placed upon each other, a person then, having his hands well wetted, touched the piece of zinc at the bottom with one hand, and the half crown at the top with the other: he felt a strong shock, which was repeated as often as the contact was renewed…"

The Morning Chronicle, London 30 May 1800.

The natural philosophers of the Eighteenth century Enlightenment, were imbued with an unwavering belief that all knowledge was good and must in some way at least be useful, even though this usefulness may not have always been apparent at the time. In this spirit Beccaria writing to his colleague Boscovich, on the fascinating yet little understood phenomenon of

statically generated electricity in April 1768, wrote, "...Electricity reveals new worlds. They are pigmy worlds, you may think, but who knows that one day giants too may amuse themselves with them".

For the following generation natural philosophers continued with their researches into electricity building on the foundations that had been laid by Franklin, Beccaria and others, until one day in 1799 a breakthrough was made by a certain Italian philosopher by the name of Alessandro Volta. This discovery remained totally obscure to the general public at large, but created great interest among the learned "philosophic" elite of the time. Thus it was that in an obscure article of the London Morning Chronicle by an anonymous journalist on 30 May 1830, one of the most momentous scientific discoveries in history was announced to the world. None at that time, including it's discover had the slightest idea of its significance and how it would transform the world. For the first time in history the curious force of electricity had been harnessed into a form by which it could be stored and utilized. Alessandro Volta had constructed the world's first battery. It was the beginning of the electrical age that would transform the world forever. Even though the long term implications were unknowable, the discovery fascinated the learned of Europe. Volta was called to present his invention to no less a personage than Napoleon Bonaparte himself. Bonaparte was so intrigued by the device, that he enthusiastically acclaimed the new "French" invention, (after the battle of Marengo Lombardy had been incorporated into the territories of the French Empire) and made Volta a Count. Napoleon's motives were not entirely "philosophic" however. Although an adherent to the new enlightenment philosophies, his reasons for the promotion and edification of Volta had more to do with a propagandist demonstration to the rest of Europe of the cultural and enlightened superiority of France. It was also meant as a reassurance to the learned elite of Europe of the honourable and progressive intentions of the ever expanding reach of Bonaparte himself. Volta himself, had not deliberately set out to "harness" the phenomenon of electricity for the future benefit of mankind, whatever that might be. In fact he had produced his "Voltaic battery" in order to refute an archaic concept on "Galvanism" and "animal electricity". Basing his discovery in part on the work of the Englishman, Nicholson in attempting to recreate nature itself, by building an artificial "electric fish".

Volta expected that his invention may possibly have some application in the field of medicine, however in a rapidly industrializing age its possible application to motion, mechanics and engines of various kinds was not lost to others. Contrary to their expectations however the earliest successful applications of the harnessing of electricity would occur in the fields of chemistry and communications in the form of the revolutionary new telegraph. In the early Twentieth century, giants of invention such as Thomas Edison together with the captains of industry (Beaccaria's giants) would eventually usher in the electrical age. Volta's recent biographer Giuliano Pancaldi, mused "How are we to account for the natural philosopher's inability to predict how and where their "useful knowledge" was going to become really useful? How do unintended consequences arise in a field like science and technology that we have been taught to regard as a well-disciplined field of human endeavour? And note that even today, in what we regard as a mature technological age, scientists and technologists do not perform much better than their late Eighteenth century predecessors in predicting the useful applications of scientific and technological research". Beccaria's speculation to his friend in 1768 that one day electricity would dominate the world was entirely correct. Progress over the ensuing centuries has been nothing short of miraculous. It is interesting to note that the medical consequences of inventions are also sometimes entirely unpredictable in some cases. Today's version of Volta's invention can be inadvertently swallowed by a small child!

BUTTON BATTERY INGESTIONS

Introduction

Disc (or button) battery ingestion can be a potentially serious, even lethal problem if they lodge within the oesophagus.

Ingestion of button batteries is most commonly seen in the paediatric age group, especially less than 6 years of age.

By far the most likely place of lodgement will be the **oesophagus**.

The risk of lodgement in the oesophagus directly relates to the size of the battery - batteries > **20 mm** pose the greatest risk.

Oesophageal burns may have potentially lethal complications, and this will mandate **endoscopic removal**.

Traditional recommendations suggested that endoscopic removal from the oesophagus should occur within 6 hours of ingestion, however, current expert opinion recommends removal from the oesophagus should *ideally* occur within **2 hours**, and the sooner the better. [1]

Chemistry

Disk batteries consist of metals and metal oxides separated by an electrolyte soaked medium.

The whole is encased then in a 2 part metal casing held together by a plastic ring that electrically insulates the anode from the cathode.

The metal undergoes oxidation on one side, while the metal oxide is reduced to the metal on the other side, producing a current when a conductive pathway is provided.

Disc batteries contain various potentially toxic heavy metals such as mercury, nickel and cadmium.

Disk batteries generally vary from 7.9 - 23 mm in diameter and vary in weight from 1-10 grams.

Pathophysiology

Complications:

Complications of disc battery ingestion include:

1. Oesophageal burns:

   With prolonged mucosal contact:

- **Chemical burns** may occur with leakage of alkaline substances such as NaOH, but the most significant mechanism of injury is the **generation** of **NaOH** at the negative pole of the battery, due to electrical currents created within in tissue.

  Significant corrosive injury can occur in as little as **2 hours** of ingestion.

  ♥ The degree of injury will depend on:

  ♥ The size of the current generated

  ♥ The exact location and orientation of the battery

  ♥ The length of time the battery remains in contact with tissue.

Oesophageal injury is by far the most serious problem with disc battery ingestion.

The following complications may arise from the chemical burns:

- **Oesophageal perforation**, with the consequent development of a chemical mediastinitis. This will be quickly followed by a bacterial mediastinitis which has high mortality if untreated.

- Oesophageal strictures

- Oesophageal fistulas into the trachea or even the aorta.

2. Aspiration of the disc battery into the airway.

3. Heavy metal poisoning:

   - Modern button batteries contain a range of heavy metals, including, silver, manganese, zinc and mercury. They may also contain lithium

     These **rarely** pose a problem in practice however.

     The larger mercury batteries are the most likely to corrode and fragment and free mercury has been demonstrated on plain radiography within the GIT together with elevated blood levels of mercury, though specific treatment is not warranted, unless symptoms develop.

Disc battery passage through the GIT:

Approximate battery transit times through the GIT tract are:

- 25 % within 24 hours

- 60 % within 48 hours

- 80 % within 72 hours

- 90 % within 96 hours.
- Only around 1% of batteries take more than 2 weeks.

Risk Assessment

Most ingested button batteries of **< 20 mm** diameter will pass through the GIT without ill effect.

Button batteries of **> 20 mm** diameter may become lodged in the oesophagus.

Button batteries may cause oesophageal perforation if lodged within the oesophagus for **2 hours or more.**

It should be noted that **aural** or **nasal** button batteries also have the potential to cause corrosive injury.

Co-ingestion of a **magnet** mandates early endoscopy and removal no matter what the position of the objects.

Clinical assessment

Important points of history

1. The child may be symptomatic, but the parent gives a history of ingestion or suspected ingestion.

2. There may be a history of sudden coughing or choking.

3 Note that the onset of symptoms due to oesophageal perforation may not become apparent for up to 28 days.

   Symptoms relating to strictures may not develop until weeks or even months post injury.

Important points of examination

1. Assessment of the adequacy of the airway will be the first priority (see also airway foreign body and stridor documents).

2. A disc battery lodged in the upper oesophagus can cause distressing symptoms, however these will not usually be immediately life-threatening.

3. Drooling may be prominent.

4. The ability of the patient to talk suggests oesophageal lodgement rather than airway lodgement.

Investigations

Plain radiography:

The only investigation that will be required is a prompt neck/chest/abdominal radiograph.

In small children an adequate view can usually be taken with a single radiograph.

Look for the battery lodged above the level of the diaphragm and so in the oesophagus:

- On AP views a disc battery will appear as an O ("O" for oesophagus) as the long axis will tend to line up with the longest axis of the oesophagus which is in the coronal plane.

- On AP views a disc battery will appear as an I ("T" for trachea) as the long axis will tend to line up with the longest axis of the trachea which is in the sagittal plane.

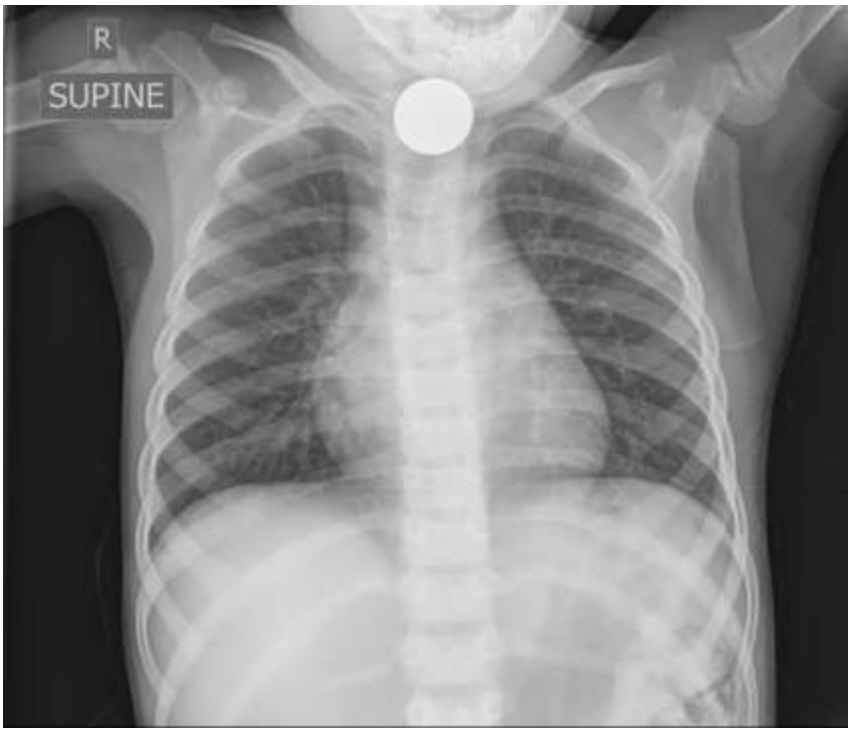

Button battery lodged in the oesophagus of a 3 year old child. Note that in A-P projection a disc shape object (such as a button battery) will align in the coronal plane. On the lateral view the object is seen to lie behind the trachea.

Follow-up radiology:

Plain radiographs are useful for following the progress of the disc battery through the GIT.

Delays in passage, especially at the pylorus of the stomach for **4 days** or more and evidence of fragmentation or leaking of heavy metals into the GIT should be looked for.

Once the battery has passed beyond the pylorus of the stomach, passage is very likely, and follow -up is not necessary unless symptoms develop.

A follow-up x-ray may be done at 10 - 14 days post ingestion to confirm passage, if passage in the stool has not be noticed.

Endoscopy:

This is, of course, required for management, i.e. removal of the button battery

The degree of injury can also be directly visualized and assessed.

If mucosal burns are visualized, then further investigation will be necessary to exclude, oesophageal perforation.

Management

1. ABC:

   - Treat any immediate airway problem, if the battery is lodged in the larynx.
   - In general batteries lodged in the oesophagus cause distressing symptoms, but will not need any *immediate* intervention.
   - Gentle suctioning of the mouth may be useful if there is excessive drooling.

2. Child handling:

   - Reassurance, as appropriate to both child and parent is important.
   - Minimal handling of child to reduce distress.
   - Attempts at IV access are not necessary if the patient's airway and conscious state are stable.

3. Endoscopic retrieval:

   Indications for endoscopic retrieval of disc batteries include:

   Definite:

   - **If the button battery is lodged in the oesophagus, then it will need endoscopic retrieval.**

     This should ideally be done within 2 hours of ingestion.

   - **Bronchial tree lodgement is uncommon but will also mandate endoscopic retrieval, also as soon as possible**

Strong consideration:

- If there is hold up within the **stomach** at the pylorus for **4 days** or more, especially for larger (> 20 mm) batteries.
- If significant *symptoms*, develop such as:
  - ♥ Pain
  - ♥ GIT bleeding
- Fragmentation of the battery or heavy metal material loose within the GIT is demonstrated on x-ray.

4. The following are **not** recommended:
   - Attempts at retrieval with a Foley balloon catheter.
   - Administration of ipecac. The battery may simply move from the stomach and lodge in the oesophagus or be aspirated into the airway.
5. Heavy metal poisoning:
   - This is not usually a clinically significant problem.
   - Occasionally the larger mercury containing batteries may fragment and mercury levels may be detected within the bloodstream.

     Treatment will probably not be required however other than careful monitoring, unless toxic symptoms occur. The advice of a specialist toxicologist should be sought in these scenarios.
6. Batteries lodged in the ear or nose:
   - These should also be removed on an urgent basis.

Disposition

Any patient with a disc battery lodged in the oesophagus must have an urgent referral to an endoscopist for removal, ideally within **2 hours** of ingestion.

If the battery is within the stomach, and the patient has no symptoms, then a review should occur at **4 days**, for repeat radiograph, especially for larger (> 20 mm) batteries. If the battery is still within the stomach, then it may be that passage through the pylorus is not possible and endoscopic removal may then be considered.

If the battery has passed beyond the stomach, then it is very likely that it will pass completely.

If **symptoms** develop at any time, the patient should be urgently reviewed in the ED for further assessment and consideration of endoscopic/ surgical removal.

Appendix 1

Button battery in the stomach of a 30 month old boy. Arrangements were made for a follow up x-ray at 48 hours to look for hold up at the pylorus. Note that in a small child the neck, chest and abdomen can all be imaged with a single radiograph, thus minimising radiation exposure. (Radiograph, courtesy Dr Kristine Gilbert).



Volta's crown of cups and column batteries, Philosophical Transactions, 1800.

References

1. Button Batteries in L Murray et al. Toxicology Handbook 3rd ed 2015.

2. Litovitz T, Schmitz BF. Ingestion of cylindrical and button batteries: an analysis of 2382 cases. *Pediatrics*. Apr 1992; 89 (4 Pt 2): 747-57.

Dr. J. Hayes
Reviewed 19 September 2017.