THE NORTHERN HOSPITAL

ACS- RIGHT VENTRICULAR ST ELEVATION MYOCARDIAL INFARCTION

"Pope Innocent X" , oil on canvas, 1650, Diego Rodriguez de Silva Velazquez, Galleria Doria-Pamphilj, Rome.

.... "Troppo vero!" (...It's too true!), Pope Innocent X on seeing his portrait by Diego Velazquez for the first time.

Suddenly the nervous chatter amoung the small group of Spaniards and assorted Vatican functionaries, comes to an abrupt halt. Velazquez glances nervously down the hallway. It is the Pope himself, accompanied by a great host of attendants and grandees. The crowd begins to part silently, as the Pope draws nearer, figures falling to their knees one by one as he approaches. Innocent is a moody and difficult man, prone to sudden outbursts of rage. He is also a busy and impatient man. How will he react to Velázquez' portrait - will he approve? Will he not approve? - worse, will he be completely indifferent - it is well known that he is no great patron of the Arts, as Bernini had found out - will he insult Velasquez? The tension in the air is palpable - all look at the floor, not daring to meet the Pontiff's eye. A Papal assistant hastens to the Portrait to make a few final adjustments. Now there is complete silence.

Velázquez: Kneeling: "....Your Holiness"

Innocent: Quietly: "Good morning Diego"

But the Pope seems not even to notice the great Spanish painter....his hand is held out for Diego to kiss, but his gaze is transfixed on the portrait. He seems angry, his face suffused with the familiar rose flush, that his courtiers instantly recognize as the heralding of an outburst of his ungoverned fury. Papal attendants tremble, scarcely breathing, many wondering if there will be an international incident. The Pope stands frozen staring at the image for many moments, not uttering a single word. His angry eyes staring deeply into the canvas. Diego can stand the tension no longer - and looks up.

Velázquez: ".....Holiness?"

Innocent makes as to turn on Diego, then suddenly looks to the ground, as if to check himself.

Innocent: "...It is too true!", he whispers.

With that single comment - the audience is over. Innocent turns abruptly and recedes swiftly back down the hallway, followed by his attendants struggling to keep pace. Velázquez and the others relax - they acknowledge each other with subtle glances of satisfaction - it's as much in the way of praise as they could possibly have hoped for from Innocent.

Pope Innocent X reigned over the catholic world from 1644-1655, a time which included the last years of the Thirty Years War - the most destructive and vicious conflict in European history up until that time, and would remain so until the time of the French Revolution and the Napoleonic Wars of the late Eighteenth and early Nineteenth centuries. The Thirty years war was a war of the very worst kind - a war of religion - Catholic and Protestant - to determine no less an issue than the individual's right to follow the religion of their choice. To the Papacy it was a fight that had to be won. The slaughter and destruction began in 1618 with the so called incident of the "Defenestration of Prague"; defenestration referring to the practice of throwing one's political opponents from a window to their deaths - in this case when a group of Protestants threw a group a Catholics from a window. This incident was said to have initiated the sickening religious conflict that would last an entire generation.

In 1555, the Peace of Augsburg had settled religious disputes within the Holy Roman Empire by establishing the principle of "Cuius regio, eius religio", which allowed an individual prince to determine the religion of his subjects. The Papacy had never recognized this principle. Indeed it did not recognize any heretical Protestant version of Christianity. The Thirty Years war was essentially fought over this issue. In the end however it would be a secular agreement between Catholic and Protestant Monarchs that brought the conflict to an end. If the war started out as one of religion, by its end it had become essentially a political one. After a generation there were many in central Europe who had known nothing but war for the whole of their lives. In 1648 the Peace of Westphalia brought the long bitter dispute between Catholic and Protestant to an end. The Catholic powers including France, Spain and parts of the Holy Roman Empire finally conceded to the Protestants the principle of "Cuius regio, eius religio". All the great powers signed the peace - in isolation to the Papacy. For the first time in history the Papacy had been marginalized in matters of state and would never again be able to rule over nations on the basis of religious hegemony. Innocent could never accept this. He issued a formal public condemnation of the Peace, entitled the "Zelo domus Dei", (Out of Zeal for the House of God) in which he declared, that the "concessions granted for all time to the heretics and their successors, (namely the Protestants), be utterly null void, invalid, iniquitous, unjust, condemnable, reprobate, inane, and without legal force or effect". But the world had moved on - he was simply ignored by Catholic and Protestant Monarchs alike. The Peace of Westphalia marked a watershed in history, dividing the modern secular age from that of a previous age of religion.

What makes a great work of Art? The answer is - many things - including technical brilliance, the very first example of a new form or a new concept, the very historical circumstances a work was created in and so its historical documentary importance, its pure aesthetic beauty, but amoung these is also the ability to convey a deep emotional response - to convey the very essence of a scene, a personality, or an emotion that transcends the contexts of time and space. This latter ability lies at the very heart of much of modern art and as such Velázquez's portrait of Innocent X - is most certainly a great work of Art as it captured the very innermost soul of the angry and raging Pope who after a generation of bitter conflict saw ultimate defeat at Westphalia and has conveyed it down through the centuries. It forms not only a priceless pre-photographic Baroque age portrait of a significant historical moment in time but also of the intimate complex emotional state of a contemporary individual who witnessed it. Today people who see Velazquez's work can still be a little unsettled by it. You hear muted comments of modern day observers, "is that the Pope? He looks kind of angry....scary even doesn't he! I don't think you would want to mess with him!" Though the historical context of the story of Innocent X is now lost to most modern observers, the pure essence of the Pope's emotional state has been brilliantly extracted and conveyed to modern viewers by the abstract expressionist work of Francis Bacon in his, "Study of Innocent X, after Velazquez", of 1953. The Pope screams out his anguish to us, his hands gripping the arms of his chair seemingly trapped and impotent within some type of suffocating cage.

When we assess our patients with right ventricular infarctions, we may like Velazquez's masterpiece, be unsettled by an unfamiliar context! Something is surely wrong! We must explore this perplexing situation further by extending the artistic domain of our ECG beyond the historical convention. We will obtain the expressionist essence of the problem by the use of right ventricular leads!

ACS- RIGHT VENTRICULAR ST ELEVATION MYOCARDIAL INFARCTION

Introduction

Right ventricular infarction was first recognized in a subgroup of patients who presented with inferior wall myocardial infarctions and who demonstrated clinical evidence of acute right ventricular failure and had elevated right ventricular filling pressures despite having relatively normal left ventricular filling pressures.

Right ventricular infarction is associated with increased morbidity and mortality, and its presence defines a **high-risk subgroup** of patients with **inferior ventricular infarctions.**

Patients with right ventricular infarctions associated with inferior infarctions have higher rates of significant hypotension, bradycardia requiring pacing support, and in-hospital mortality than is the case for isolated inferior infarctions.

Right ventricular infarction is confirmed by the presence of ST elevation in the right-sided leads (V_3R-V_6R).

Management is essentially the same as for any STEMI, although there will be additional considerations relating to the maintenance of right ventricular preload.

See also separate STEMI document (in CVS folder).

Anatomy

Right ventricular infarctions are the result of proximal occlusions of the **right coronary artery.**

ST segment elevation in V_4R can distinguish patients with proximal occlusion of the right coronary artery, from those with an occlusion of the distal right coronary artery or the left circumflex artery. (*Chan 336*).

ST segment elevation in lead V_4R predicts increased morbidity and mortality in patients with inferior infarctions.

Incidence

Isolated right ventricular infarction is very uncommon. It is usually seen in association with inferior wall infarction.

Up to 30 % of inferior wall infarctions have been said to be associated with some degree of right ventricular infarction. (Chan 178, 336)

And in one half of these patients there will be haemodynamically significant consequences. (*Chan 336*)

Pathophysiology

Haemodynamic factors:

Important considerations include:

- The right ventricle is a thin-walled chamber that functions at lower oxygen demands and pressure compared to the left ventricle.

- The perfusion of the right ventricle occurs throughout the cardiac cycle in both systole and diastole, in contrast to the situation in the left ventricle where coronary artery perfusion occurs principally during diastole.

- The right ventricle has increased ability to extract oxygen during hemodynamic stress. All of the above factors make the right ventricle somewhat less susceptible to infarction as compared to the left ventricle.

- Typically, right ventricular infarction occurs when there is an occlusion of the right coronary artery proximal to the acute marginal branches, but it may also occur with an occlusion of the left circumflex artery in patients who have left-dominant coronary circulations.

Complications:

These may include:

1. Arrhythmias:

    - **AF** and **high-grade atrioventricular block** are particular considerations, but the usual complications of infarction such as VT or VF are also possible.

2. Tricuspid regurgitation.

3. Cardiogenic shock:

    - Although uncommon in RV infarction this will be the most serious complication.

4. Right ventricular free wall rupture, and cardiac tamponade, (uncommon).

5. Right to left shunt:

    - A unique, but very rare complication is the development of a right-to-left shunt through a patent foramen ovale due to raised right ventricular pressures, which should be suspected in patients who have hypoxemia that is not responsive to the administration of oxygen.

Clinical Features

A right ventricular infarct should be considered in all patients who present with an acute inferior wall myocardial infarction, especially in the setting of a low cardiac output.

Right ventricular infarction will be a diagnosis made on investigation, triggered by an index of clinical suspicion

The classical clinical triad for RV infarction with right ventricular failure is said to be:

1. Distended neck veins

2. Clear lung fields

3. Hypotension.

Infrequent addional clinical manifestations may also include:

4. Right ventricular third and fourth heart sounds, which are classically audible at the left lower sternal border and increase with inspiration.

5. Kussmaul sign, (an increase in JVP with inspiration).

Most often there will not be any clinical signs that draw the attention to the diagnosis of right ventricular infarction.

Hypotension however is one important clue, as this is not commonly seen with uncomplicated inferior infarctions, as so will raise the possibility of RV infarction, and/ or other complications such as cardiac tamponade.

Investigations

Blood tests

Other routine blood investigations as done for any STEMI, including:

1. FBE

2. U&Es/ glucose

3. Troponin levels

ECG

Ideally all patients with an inferior wall myocardial infarction should have additional right-sided ECG leads done.

The ECG features of Right Ventricular Infarction include: [2,3]

- **ST segment elevation (> 1 mm) in lead VI**

  - ♥ This is the only *standard* ECG lead that *directly* reflects the right ventricle.

- ♥ A further *refinement* is that the magnitude of ST elevation in V1 exceeds the magnitude of ST elevation in V2.

- **ST segment depression in lead V2**

  - ♥ A further refinement here includes if the ST segment in V1 is isoelectric and the ST segment in V2 is markedly depressed.

  - ♥ Note that the *combination* of ST elevation in V1 and ST depression in V2 is highly specific for right ventricular MI.

- **ST segment elevation in lead III > lead II**

  - ♥ Lead III more directly reflects the right ventricle than does lead II.

- **ST segment elevation (>2 mm) in right ventricular leads V_3R - V_6R, (confirms the diagnosis).**

  ST-segment elevation in lead **V_4R** is the single most sensitive and specific predictor of right ventricular involvement.

Lead	**Sensitivity (%)**	**Specificity (%)**
V_1	28	92
V_3R	69	97
V_4R	93	95

These changes will most commonly be seen *in association* with inferior (II, III, aVF) - STEMI.

The Placement of Right Ventricular Leads:

V3R: Half way between V2R and V4R (use V1 electrode)

V4R: Right side 5th intercostal space mid clavicular line (use V2 electrode)

VR5: Same horizontal line as V4R on right anterior axillary line (use V3 electrode)

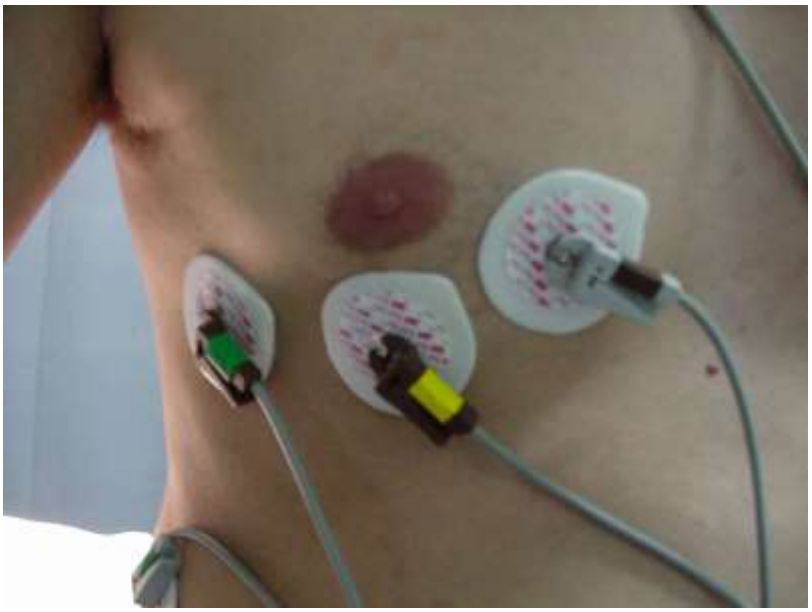

Right Ventricular leads V3R, V4R and V5R (axillary)

CXR

This will not assist in the diagnosis of right ventricular infarction, but may help rule out differential diagnoses.

Echocardiography

1. Echocardiography is very useful in demonstrating RV infarction:
    - There will be RV wall motion abnormalities.
2. It can also rule out secondary complications such as:
    - Tamponade following a free wall rupture.
    - Significant tricuspid regurgitation.
    - Right to left shunting through a patent foramen ovale.

Hemodynamic Monitoring

On hemodynamic monitoring, there is disproportionate elevation of right-sided filling pressures when compared with left-sided filling pressures. This represents the hallmark of right ventricular infarction.

Note that there is an increased risk of myocardial perforation in placing central lines and Swan Ganz catheters in RV infarction.

MRI

Cardiac MRI is the most sensitive method to assess right ventricular function, but, of course is problematic in the acute setting and should not be allowed to delay definitive management interventions.

Management

Management is the same as for any STEMI, although there will be additional considerations relating to the maintenance of right ventricular preload.

Give:

1. Morphine analgesia as required.

2. Anti-platelet therapy:

    - Aspirin

    - Ticagrelor

3. Heparin bolus (with a view to PCI)

4. Early revascularization:

    - Either by thrombolysis or by PCI and angioplasty, as indicated.

See also STEMI document (in CVS folder).

Maintenance of right ventricular preload:

The necessity of maintaining right ventricular preload differentiates the treatment of right ventricular infarction from that of predominantly left ventricular infarction.

Important considerations in this regard include:

1 Volume loading:

Cautious **volume loading** with normal saline is used in cases of hypotension, in distinction to its *far more cautious* use in anterior or left ventricular myocardial infarctions.

- As a general guide give **sodium chloride 0.9% solution 200 ml aliquots IV, over 30 minutes**, repeat dose as required [4] – (up to 500 – 1000 mls).

  During fluid loading, the patient must be observed closely for deteriorating haemodynamic status and development of left ventricular failure.

Haemodynamic monitoring is helpful to guide therapy when hypotension and oliguria fail to respond promptly, when inotropic support is needed, and when the relative contribution of left versus right ventricular dysfunction is unclear.

2. Inotropes:

- Inotropes may be necessary if volume loading fails to improve blood pressure.

3. Avoidance or caution with agents that may reduce right ventricular filling pressures:

- Agents which reduce right ventricular filling pressures, such as **diuretics, beta blockers** and **nitrates** must only be used with **great caution**, but are best avoided where possible.

  These agents may produce severe hypotension/ cardiogenic shock in situations of significant RV ischemia.

4. AF:

- Should AF complicate RV infarction in the setting of hemodynamic instability, DC cardioversion should be considered.

  In ischemic poorly functioning RV, the atrial component to right sided cardiac output becomes relatively more important.

Appendix 1

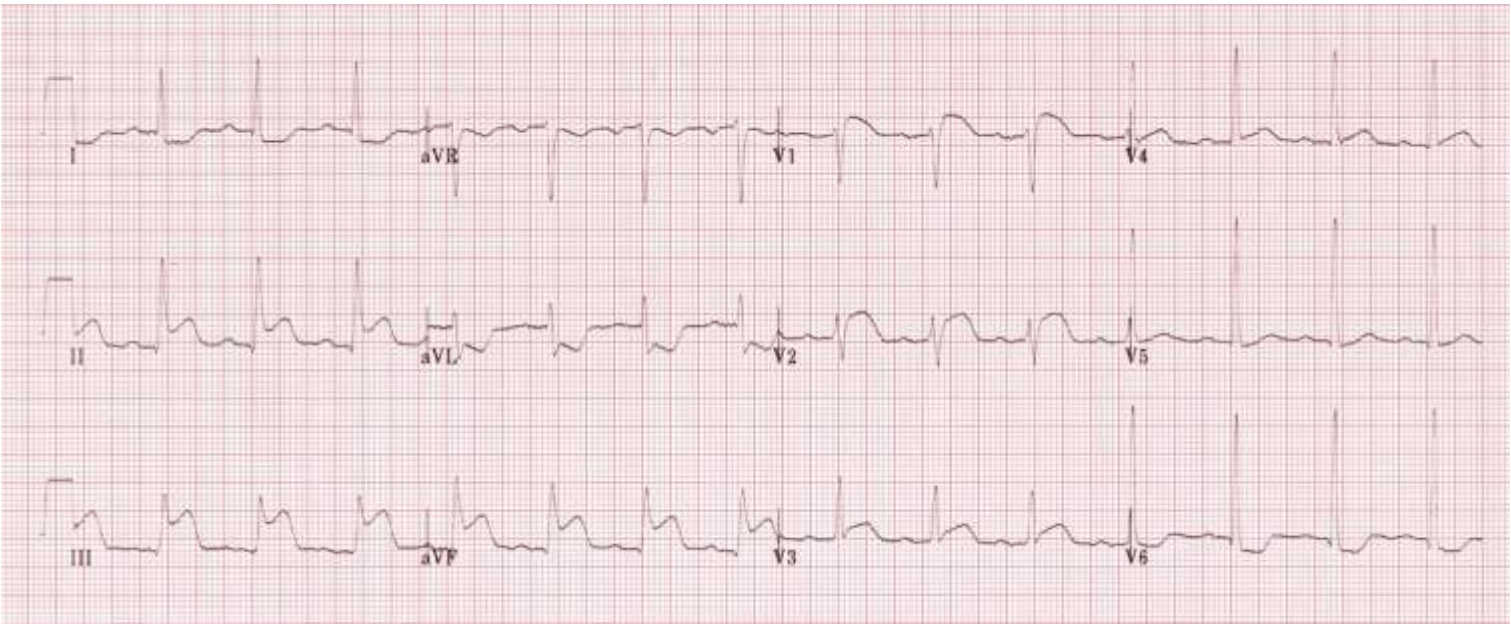

Inferior STEMI. Right ventricular infarction is suggested by, ST elevation in V1 and ST elevation in lead III > lead II.

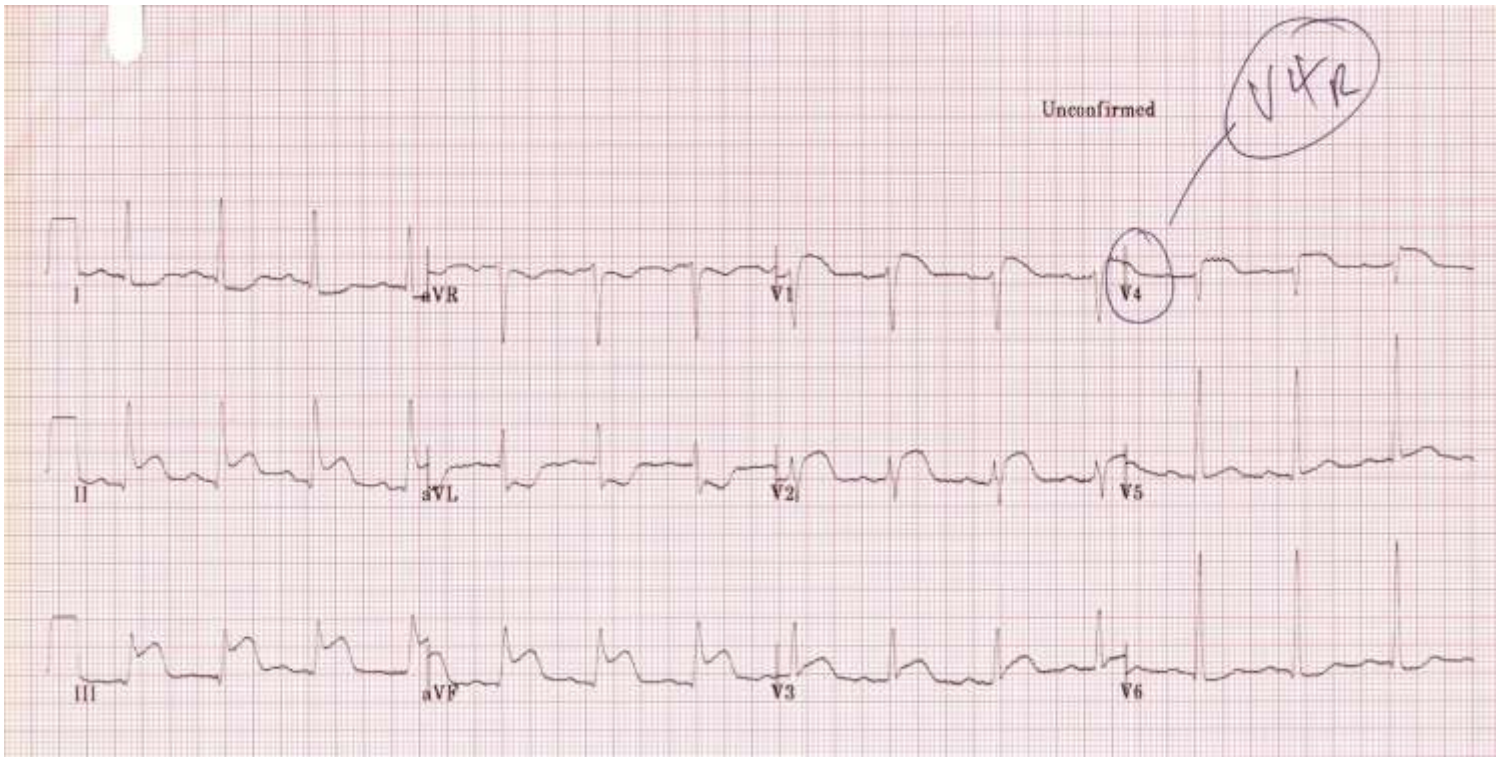

*ECG of the same patient using **right ventricular leads**. Right ventricular infarction is confirmed by ST segment elevation in V4R. (Life the Fast Lane, Website ECG Library).*

"Study after Velazquez's, Pope Innocent X", oil on canvas, Frances Bacon, 1953, Des Moines Art Center, Iowa.

References:

1. Kinch JW, Ryan TJ: Right Ventricular Infarction: NEJM vol 330 (17) April 28 1994.

2. Chan TC, Brady WJ, Harrigan RA, Ornato JP, Rosen P. ECG in Emergency Medicine and Acute Care. Elsevier Mosby 2005

3. Amal Mattu and William Brady; ECGs for the Emergency Physician. BMJ Books 2003 & 2008.

4. eTG - July 2016.

   - Cardiovascular Therapeutic Guidelines 6(1) ed 2012.

5. **Acute Coronary Syndrome Guidelines:**

   D.P Chew, I.A Scott, L. Cullen et al. National Heart Foundation of Australia & Cardiac Society of Australia and New Zealand: Australian Clinical Guidelines for the Management of Acute Coronary Syndromes 2016. Heart, Lung and Circulation (2016) 25, 895-951.

6. Guideline summary:

   D.P Chew, I.A Scott, L. Cullen et al. National Heart Foundation of Australia & Cardiac Society of Australia and New Zealand: Australian Clinical Guidelines for the Management of Acute Coronary Syndromes 2016. MJA 205 (3) 1 August 2016.

   - doi: 10.5694/mja16.00368 j

Dr J Hayes
Reviewed 3 November 2016.